



## Efficacy of different antimycotoxicosis compounds on the main immune organs and humoral immune response of broiler chickens fed on aflatoxin and/or ochratoxin contaminated diet

Amal H. T. Abdelnaser<sup>1</sup>, Anwaar M. El Nabrawy<sup>2</sup>, Kamel A. Zyan<sup>1</sup>, Sawsan, S. El Basuni<sup>1</sup>

<sup>1</sup> Department of Avian and Poultry Diseases, Faculty of Veterinary Medicine, Benha University, Qalyubia, 13736, Egypt. <sup>2</sup> Department of Avian and Poultry Diseases, Faculty of Veterinary Medicine, Cairo University, Giza, 12211, Egypt.

### ABSTRACT

The ameliorative effects of some different antimycotoxicosis compounds (AMCs) against the adverse effects induced by intoxication of dietary aflatoxin (AF) and/or ochratoxin (OT) on the immune system performance in broiler chicks were investigated. AF (23 ppb), OT (17 ppb) and mixed doses were fed and in association with antimycotoxin feed additives; product A (combination of *Eubacterium* BBSH<sup>797</sup> and *Trichosporon mycotoxinivoran*, plant extract, algae extract) or product B (nano-clay, seaweed extract, yeast cell wall, diatomaceous earth) from 1 day old chicks to 21 day. The intoxicated chicks treated with AMCs; product C (combination of bacterial cell wall extract, oligosaccharides, L-form bacteria extract, group of mycotoxin biotransforming enzymes, organic acid and salts, hepatic and renal tonic and vitamins) or product D in drinking water (isomaltoligosaccharide, micronized-mannan oligosaccharide, *lactobacillus* extract and cholestyramine) were used in the drinking water of 2 weeks old chicks after appearance of signs. Results revealed that chicks intoxicated with AF and/or OT showed significant ( $P < 0.05$ ) decrease in the relative weights of the main immune organs and the antibody titers against vaccines of Newcastle disease (ND) and Infectious bursal diseases (IBD) viruses, in addition to significant ( $P < 0.05$ ) increase in the cumulative histopathological lesion scores of thymus, bursa of Fabricius and spleen. The adverse effects of AF and/or OT on the relative weights and the histopathological lesion scores of the tested immune organs and the antibody titers against ND and IBD vaccination were significantly ( $P < 0.05$ ) improved with dietary supplementation of AMCs products A or B. While the treatment of the intoxicated chicks with AMCs products C or D in the drinking water showed partially and temporarily improvement in the relative weights and the histopathological lesion scores of the tested immune organs and did not improve the negative effects of AF and/or OT on the antibody titers against ND and IBD vaccines.

**Keywords:** Mycotoxicosis – Broiler chicken - Immunity- immune organs.

(<http://www.bvmj.bu.edu.eg>)

(BVMJ-, 33( 2): 430-446, DECEMBER, 2017)

### 1. INTRODUCTION

Mycotoxins considered as unavoidable contaminants in foods and feeds all over the world. AF and OT are the most common mycotoxins in poultry feed (Surai and Mezes, 2005).

Consumption of mycotoxins, at levels that do not cause overt clinical mycotoxicosis, can suppress the immune functions and decrease resistance to infectious disease (Resanovic et al., 2009). AF and OT

considered among major immuno-suppressive agents in poultry diets that cause immuno-modulation through inducing changes in cellular and molecular mechanisms that include inhibition of protein synthesis and lipid peroxidation and DNA damage (Bennett and Klich, 2003 and Ringot et al., 2006). Various approaches are used to detoxify, inactivate, degrade, or decrease mycotoxins in contaminated feed.

Physical, chemical and biological treatment of contaminated feed and feed stuffs was investigated (CAST, 2003). Nowadays, the inclusion of mycotoxin detoxifying agents is the most prevalent approach in the feed industry to decontaminate and/or detoxify mycotoxin. Mycotoxin detoxifying agents divided according to the European commission regulation No. 386/2009 of 12 May 2009 into two different classes; mycotoxin binders, which are sorbent materials able to remove mycotoxins by adsorption during passage in the gastrointestinal tract; and mycotoxin modifiers which include enzymes or microorganisms capable of degradation of mycotoxins into non-toxic metabolites (EFSA, 2009). It is important to know that the commercial anti-mycotoxicosis products contain one or more of mycotoxin detoxifying agents in addition to combinations from algae, plant extracts, enzymes, nutrient supplements, or traditional spices to detoxify mycotoxins from feed and to ameliorate the immunity and general health of birds. This study was carried out as a semi-field trial in broiler chickens to evaluate the efficacy of some anti-mycotoxicosis compounds, which are used in Egypt, on the immune system performance and humoral immune response of broiler chickens kept on toxic ration.

## 2. MATERIAL AND METHODS

### 2.1. Mycotoxin production and determination

Aflatoxin was produced by growing standard aflatoxigenic strain (*A. flavus* ATCC 16875) on sterile grounded corn according to Shotwell et al., (1966). While *Aspergillus ochraceous* strain ATCC 63304 was inoculated on sterile crushed corn to produce OT by use the method of Trenk et al., (1971). The mycotoxin contaminated corns were collected separately for each fungus and use affinity column chromatography to determine the AF and OT concentration (Aflatest and

Ochratest, VICAM, USA) and fluorometric analysis (Series-4Ex Fluorometer, VICAM, USA). Then mycotoxin contaminated corns were used to prepare the experimental starter diets. Finally, the levels of AF and/or OT in experimental starter diets were at 23 ppb and/or 17 ppb, respectively (El Nabarawy et al., 2016).

### 2.2. Experimental chicken, diet and design

Five hundred and twenty eight, apparently healthy one day old Arbor-Acres broiler chicks were obtained from a commercial company for poultry in Egypt to perform two experiments I and II, as illustrated in Table 1. In both experiments (I-II), group (1) served as a control negative group (0 ppb AF and/or OT), while groups 2, 5 and 8 were used as control positive groups, as illustrated in Table 1. Groups (2), (3-I), (3-II), (4-I) and (4-II) were fed on diets contaminated with 23 ppb AF, groups (5), (6-I), (6-II), (7-I) and (7-II) were fed on diets contaminated with 17 ppb OT, groups (8), (9-I), (9-II), (10-I) and (10-II) were fed on diets contaminated with 23 ppb AF and 17 ppb OT. Chickens were maintained under standard conditions of temperature and lighting regimen. Feed and water provided *adlibitum* throughout the 35-d the time of the experiment. Chickens were vaccinated against ND, Avian influenza, and IBD as shown in Table 2.

Four AMCs (A, B, C & D) were purchased from commercial companies in Egypt (Table 1). Products A and B were added to feed at 1gm/kg and 0.5 gm/kg, respectively as preventive feed antimycotoxicosis compounds for 21 days. Products C and D were added to drinking water of the intoxicated two weeks old chicks for treatment of mycotoxicosis at a dose of 1ml/liter/3 successive days and 0.5 ml/liter/one day, respectively according to the instructions of the manufacturing companies. All study protocols and procedures were approved by the committee of graduate studies and research of faculty of veterinary medicine, Benha

University (place where the experiments were conducted).

### 2.3. Sampling

Three birds from each group were randomly collected, euthanized at 7; 14<sup>th</sup> and 21<sup>th</sup> days of the experiment and subjected to the following parameters.

#### 2.3.1. The relative weight of the immune organs

Bursa of Fabricius, thymus and spleen harvested from the euthanized birds. These organs were weighed and their relative weights were calculated as according to Verma et al., (2004) as organs weight/live BW ×100.

#### 2.3.2. Histopathological examination

The tissue samples were taken from the spleen, thymus and bursa of Fabricius and Table (1) Design of the experiments

fixed in 10 % buffered formalin. The tissue processing and the staining procedure of tissue sections were applied according to Scheur and Chalk (1986).

*Histopathological lesions scoring:* During microscopic examination of prepared slides of tissue sections for each replicate, each histopathological lesion was assigned a value from 0-3 depending upon the absence (0) and intensity (1-3). Value assigned for a particular lesion of the examined organs was added to obtain an individual lesion score. Individual lesion scores of all the lesions were summed up to obtained a lesion score for a particular time. A cumulative score for a group was obtained by summation of all lesion scores of that group (Hussain, 2006).

Group *	Chick No. /group	Contaminated diet**		Antimycotoxins compounds			
				Experiment I*		Experiment II**	
				AF	OT	Product A	Product B
Group 1	33	-	-	-	-	-	-
Group 2	33	+	-	-	-	-	-
Group 3	I/33	+	-	+	-	-	-
	II/33	+	-	-	-	+	-
Group 4	I/33	+	-	-	+	-	-
	II/33	+	-	-	-	-	+
Group 5	33	-	+	-	-	-	-
Group 6	I/33	-	+	+	-	-	-
	II/33	-	+	-	-	+	-
Group 7	I/33	-	+	-	+	-	-
	II/33	-	+	-	-	-	+
Group 8	33	+	+	-	-	-	-
Group 9	I/33	+	+	+	-	-	-
	II/33	+	+	-	-	+	-
Group 10	I/33	+	+	-	+	-	-
	II/33	+	+	-	-	-	+

(\*) Group (1) served as a control negative group (0 ppb AF and/or OT), while groups 2, 5 and 8 were used as control positive groups in both experiments I and II. Each group was divided into 3 replicate (11 chicks/replicate).(\*\*) Mycotoxin concentration in contaminated diets: 23ppb AF and/or 17 ppb OT.

Table (2) Vaccination program used for chicks during the experiments

Age	Vaccine	Type and dose	Route	Company/ batch No.
7 D	Izovac Hitchner B <sub>1</sub>	Live – 10 <sup>6.5</sup> ID <sub>50</sub>	Drinking water	IZO, Italy
10 D	Volvac AI+ND	Killed-ND(10 <sup>8.2</sup> ID <sub>50</sub> ) AI (10 <sup>7.6</sup> ID <sub>50</sub> )	Subcutaneous injection	Boehringer Ingelheim, Mexico/1307008A
12 D	Izovac Gumboro 2	Live intermediate IBDv– 10 <sup>5</sup> ID <sub>50</sub>	Drinking water	IZO, Italy
18 D	Nobilis Colon 30	Live – 10 <sup>6</sup> ID <sub>50</sub>	Drinking water	IZO, Italy/ GOV5 N 4803461
28 D	Nobilis Colon 30	Live – 10 <sup>6</sup> ID <sub>50</sub>	Drinking water	IZO, Italy/ GOV5 N 4803461

### 2.3.3. Estimation of humoral immune response

Blood samples were collected in non-heparinized tubes by jugular vein puncture at zero day, 7<sup>th</sup>, 14<sup>th</sup> and 21<sup>st</sup> day of chick's age. Sera were separated and stored at - 20 °C for subsequent assessment of antibody titers against vaccination of ND virus use HI test (OIE, 2012) and assessment of antibody titers against vaccines of IBD virus, use specific ELISA kits (BioChek Veterinary Diagnostics, Hounslow, Holland) in accordance with the protocol specified by the supplier

### 2.4. Statistical analysis

Differences between groups were analyzed by use One-Way ANOVA and \*-Duncan's multiple comparison Post Hoc tests (Duncan, 1955). Statistical analysis was performed use the statistical software package SPSS for Windows (version 20.0, SPSS Inc., Chicago, IL, USA). Statistical significance between mean values was set at (P < 0.05).

Table (1) Design of the experiments

## 3. RESULTS

### 3.1. Relative weights of the main immune organs

Dietary supplementation of AMCs A or B showed significant (P < 0.05) increase in the spleen relative weight of chicks at the

3<sup>rd</sup> week of experiment in the groups 6, 7, 9 and 10 when compared with control positive groups 5 & 8 (Tables 3) as well as significant (P < 0.05) increase in the thymus relative weight of chicks in the groups 3, 4, 9 and 10 when compared with control positive groups 2 & 8 (Table 5). The addition of AMC products A or B to single contaminated diet with AF or OT showed non significant (P > 0.05) difference in the relative weight of bursa of Fabricius in groups 3, 4, 6 and 7 with the control negative group at the 3<sup>rd</sup> week of experiment (Table 7).

Data in Table 4 shows non-significant (P > 0.05) difference in the spleen, relative weight of birds with the use of AMC products C or D for the treatment of chicks intoxicated with AF and/or OT in the 3<sup>rd</sup> week of experiment II. The use of AMC product D in the treatment of chicks in the groups 7 and 10 in the 3<sup>rd</sup> week of experiment II showed significant (P < 0.05) increase in the thymus and spleen relative weights of chicks when compared with control positive groups 5 and 8 (Tables 4 & 6). Moreover, relative weight of bursa of Fabricius reported significant (P < 0.05) increase with the use of AMC product C for treating chicks intoxicated with AF (group 3) and product D in treating chicks of groups 7 & 10 during the 3<sup>rd</sup> week of experiment II (Table 8).

Table (3) The effect of investigated antimycotoxigenic compounds used as feed additives on relative weight of spleen in the broiler chicken

Group	Treatment	Relative weight of the Spleen (g/100 g of BW)		
		1 <sup>st</sup> Week	2 <sup>nd</sup> Week	3 <sup>rd</sup> Week
1	Control (-ve)	0.13±0.00 <sup>ab</sup>	0.15±0.00 <sup>a</sup>	0.11±0.00 <sup>bc</sup>
2	AF	0.14±0.01 <sup>a</sup>	0.14±0.01 <sup>a</sup>	0.10±0.01 <sup>cd</sup>
3	AF+ prod. A	0.12±0.00 <sup>bc</sup>	0.14±0.00 <sup>a</sup>	0.12±0.02 <sup>ab</sup>
4	AF+ prod. B	0.13±0.01 <sup>a</sup>	0.14±0.01 <sup>a</sup>	0.09±0.02 <sup>d</sup>
5	OT	0.10±0.00 <sup>de</sup>	0.04±0.00 <sup>e</sup>	0.06±0.01 <sup>e</sup>
6	OT+ prod. A	0.12±0.00 <sup>bc</sup>	0.14±0.01 <sup>a</sup>	0.09±0.00 <sup>d</sup>
7	OT+ prod. B	0.12±0.01 <sup>bc</sup>	0.09±0.00 <sup>c</sup>	0.09±0.00 <sup>d</sup>
8	AF+OT	0.09±0.00 <sup>e</sup>	0.06±0.01 <sup>d</sup>	0.06±0.01 <sup>e</sup>
9	AF+OT+ prod. A	0.11±0.00 <sup>cd</sup>	0.14±0.00 <sup>a</sup>	0.13±0.01 <sup>a</sup>
10	AF+OT+ prod. B	0.12±0.01 <sup>bc</sup>	0.11±0.01 <sup>b</sup>	0.12±0.01 <sup>ab</sup>

“a, b & c”: There is significant difference (P<0.05) between any two means, within the same column have the different superscript letter. AMC in experiment (I): antimycotoxigenic compounds / starter feed from 1 to 21 day of chick age\* Prod. A: combination of *Eubacterium* BBSH<sup>797</sup> and *Trichosporon mycotoxinivoran*; plant extract; algae extract. \*\* Prod. B: formed from nano-clay; seaweed extract; yeast cell wall; diatomaceous earth

Table (4) The effect of investigated antimycotoxigenic compounds used in the drinking water on relative weight of spleen in the broiler chicken

Group	Treatment	Relative weight of the spleen (g/100 g of BW)		
		1 <sup>st</sup> Week	2 <sup>nd</sup> Week	3 <sup>rd</sup> Week
1	Control (-ve)	0.13±0.0 <sup>a</sup>	0.15±0.0 <sup>a</sup>	0.11±0.0 <sup>ab</sup>
2	AF	0.14±0.01 <sup>a</sup>	0.14±0.01 <sup>ab</sup>	0.10±0.01 <sup>ab</sup>
3	AF+ prod. C	0.13±0.01 <sup>a</sup>	0.13±0.0 <sup>b</sup>	0.10±0.0 <sup>ab</sup>
4	AF+ prod. D	0.13±0.0 <sup>a</sup>	0.13±0.0 <sup>a</sup>	0.10±0.01 <sup>ab</sup>
5	OT	0.10±0.0 <sup>b</sup>	0.04±0.0 <sup>d</sup>	0.06±0.01 <sup>c</sup>
6	OT+ prod. C	0.10±0.0 <sup>b</sup>	0.04±0.0 <sup>d</sup>	0.07±0.01 <sup>bc</sup>
7	OT+ prod. D	0.09±0.0 <sup>b</sup>	0.03±0.0 <sup>d</sup>	0.11±0.01 <sup>ab</sup>
8	AF+OT	0.09±0.0 <sup>b</sup>	0.06±0.01 <sup>c</sup>	0.06±0.01 <sup>c</sup>
9	AF+OT+ prod. C	0.09±0.0 <sup>b</sup>	0.04±0.01 <sup>d</sup>	0.13±0.0 <sup>a</sup>
10	AF+OT+ prod. D	0.09±0.0 <sup>b</sup>	0.04±0.0 <sup>d</sup>	0.12±0.02 <sup>a</sup>

“a, b & c”: There is significant difference (P<0.05) between any two means, within the same column have the different superscript letter. AMC in experiment (II): antimycotoxigenic compounds of 2 weeks old chicks after appearance of signs\* Prod. C: combination of bacterial cell wall extract; oligosaccharides; L-form bacteria extract; group of mycotoxin biotransforming enzymes; organic acid and salts; hepatic and renal tonic; vitamins. \*\* Prod. D: formed from isomalto-oligosaccharide; micronized-mannan-oligosaccharide; *Lactobacillus* extract; cholestyramine

Table (5) the effect of investigated antimycotoxigenic compounds used as feed additives on relative weight of thymus in the broiler chicken

Group	Treatment	Relative weight of thymus (g/100 g of BW)		
		1 <sup>st</sup> Week	2 <sup>nd</sup> Week	3 <sup>rd</sup> Week
1	Control (-ve)	0.26±0.01 <sup>a</sup>	0.45±0.02 <sup>ab</sup>	0.55±0.02 <sup>a</sup>
2	AF	0.25±0.01 <sup>ab</sup>	0.33±0.01 <sup>e</sup>	0.27±0.02 <sup>f</sup>
3	AF+ prod. A	0.25±0.00 <sup>ab</sup>	0.38±0.02 <sup>cde</sup>	0.48±0.08 <sup>bc</sup>
4	AF+ prod. B	0.29±0.02 <sup>a</sup>	0.49±0.02 <sup>a</sup>	0.39±0.07 <sup>e</sup>
5	OT	0.17±0.01 <sup>c</sup>	0.33±0.02 <sup>e</sup>	0.46±0.01 <sup>cd</sup>
6	OT+ prod. A	0.19±0.00 <sup>c</sup>	0.41±0.02 <sup>bc</sup>	0.52±0.07 <sup>ab</sup>
7	OT+ prod. B	0.20±0.01 <sup>bc</sup>	0.41±0.03 <sup>bc</sup>	0.41±0.02 <sup>de</sup>
8	AF+OT	0.16±0.01 <sup>c</sup>	0.39±0.02 <sup>cd</sup>	0.29±0.02 <sup>f</sup>
9	AF+OT+ prod. A	0.25±0.01 <sup>ab</sup>	0.39±0.02 <sup>cd</sup>	0.47±0.05 <sup>bc</sup>
10	AF+OT+ prod. B	0.26±0.00 <sup>a</sup>	0.42±0.01 <sup>bc</sup>	0.39±0.06 <sup>e</sup>

“a, b & c”: There is significant difference (P<0.05) between any two means, within the same column have the different superscript letter. AMC in experiment (I): antimycotoxigenic compounds / starter feed from 1 to 21 day of chick age\* Prod. A: combination of *Eubacterium* BBSH<sup>797</sup> and *Trichosporon mycotoxinivoran*; plant extract; algae extract. \*\* Prod. B: formed from nano-clay; seaweed extract; yeast cell wall; diatomaceous earth

Table (6) the effect of investigated antimycotoxigenic compounds used in the drinking water on relative weight of thymus in the broiler chicken

Group	Treatment	Relative weight of thymus (g/100 g of BW)		
		1 <sup>st</sup> Week	2 <sup>nd</sup> Week	3 <sup>rd</sup> Week
1	Control (-ve)	0.26±0.01 <sup>a</sup>	0.45±0.02 <sup>a</sup>	0.55±0.02 <sup>a</sup>
2	AF	0.25±0.01 <sup>a</sup>	0.33±0.01 <sup>c</sup>	0.27±0.02 <sup>d</sup>
3	AF+ prod. C	0.23±0.02 <sup>a</sup>	0.32±0.00 <sup>c</sup>	0.43±0.01 <sup>b</sup>
4	AF+ prod. D	0.23±0.03 <sup>a</sup>	0.32±0.01 <sup>c</sup>	0.46±0.06 <sup>b</sup>
5	OT	0.17±0.01 <sup>b</sup>	0.33±0.02 <sup>c</sup>	0.46±0.01 <sup>b</sup>
6	OT+ prod. C	0.17±0.01 <sup>b</sup>	0.30±0.01 <sup>c</sup>	0.44±0.01 <sup>b</sup>
7	OT+ prod. D	0.16±0.01 <sup>b</sup>	0.29±0.01 <sup>c</sup>	0.56±0.02 <sup>a</sup>
8	AF+OT	0.16±0.01 <sup>b</sup>	0.39±0.02 <sup>b</sup>	0.29±0.02 <sup>d</sup>
9	AF+OT+ prod. C	0.17±0.01 <sup>b</sup>	0.29±0.02 <sup>c</sup>	0.36±0.10 <sup>c</sup>
10	AF+OT+ prod. D	0.16±0.01 <sup>b</sup>	0.29±0.01 <sup>c</sup>	0.48±0.01 <sup>b</sup>

“a, b & c”: There is significant difference (P<0.05) between any two means, within the same column have the different superscript letter. AMC in experiment (II): antimycotoxigenic compounds in drinking water of 2 weeks old chicks after appearance of signs\* Prod. C: combination of bacterial cell wall extract; oligosaccharides; L-form bacteria extract; group of mycotoxin bio transforming enzymes; organic acid and salts; hepatic and renal tonic; vitamins. \*\* Prod. D: formed from Isomalto-oligosaccharide; micronized-mannan-oligosaccharide; lactobacillus extract; cholestyramine

Efficacy of different antimycotoxicosis compounds

Table (7) the effect of investigated antimycotoxicosis compounds used as feed additives on relative weight of Bursa of Fabricius in the broiler chicken

Group	Treatment	Relative weight of the Bursa of Fabricius (g/100 g of BW)		
		1 <sup>st</sup> Week	2 <sup>nd</sup> Week	3 <sup>rd</sup> Week
1	Control (-ve)	0.20±0.01 <sup>a</sup>	0.10±0.0 <sup>a</sup>	0.13±0.02 <sup>abc</sup>
2	AF	0.15±0.01 <sup>bc</sup>	0.09±0.01 <sup>ab</sup>	0.12±0.03 <sup>bc</sup>
3	AF+ prod. A	0.17±0.00 <sup>ab</sup>	0.09±0.00 <sup>ab</sup>	0.15±0.04 <sup>a</sup>
4	AF+ prod. B	0.20±0.01 <sup>a</sup>	0.11±0.01 <sup>a</sup>	0.13±0.03 <sup>abc</sup>
5	OT	0.12±0.01 <sup>cd</sup>	0.07±0.01 <sup>b</sup>	0.12±0.02 <sup>bc</sup>
6	OT+ prod. A	0.17±0.01 <sup>ab</sup>	0.08±0.00 <sup>b</sup>	0.14±0.04 <sup>ab</sup>
7	OT+ prod. B	0.19±0.01 <sup>a</sup>	0.09±0.00 <sup>ab</sup>	0.15±0.02 <sup>a</sup>
8	AF+OT	0.10±0.01 <sup>d</sup>	0.08±0.00 <sup>b</sup>	0.14±0.03 <sup>ab</sup>
9	AF+OT+ prod. A	0.14±0.00 <sup>bc</sup>	0.08±0.00 <sup>b</sup>	0.16±0.01 <sup>a</sup>
10	AF+OT+ prod. B	0.14±0.00 <sup>bc</sup>	0.08±0.00 <sup>b</sup>	0.11±0.01 <sup>c</sup>

“a, b & c”: There is significant difference (P<0.05) between any two means, within the same column have the different superscript letter. AMC in experiment (I): antimycotoxicosis compounds / starter feed from 1 to 21 day of chick age\* Prod. A: combination of *Eubacterium* BBSH<sup>797</sup> and *Trichosporonmycotoxinivoran*; plant extract; algae extract. \*\* Prod. B: formed from nano-clay; seaweed extract; yeast cell wall; diatomaceous earth

Table (8) the effect of investigated antimycotoxicosis compounds used in the drinking water on relative weight of Bursa of Fabricius in the broiler

Group	Treatment	Relative weight of Bursa of Fabricius (g/100 g of BW)		
		1 <sup>st</sup> Week	2 <sup>nd</sup> Week	3 <sup>rd</sup> Week
1	Control (-ve)	0.20±0.01 <sup>a</sup>	0.10±0.00 <sup>a</sup>	0.13±0.02 <sup>def</sup>
2	AF	0.15±0.01 <sup>b</sup>	0.09±0.01 <sup>ab</sup>	0.12±0.03 <sup>ef</sup>
3	AF+ prod. C	0.14±0.00 <sup>b</sup>	0.09±0.00 <sup>ab</sup>	0.17±0.01 <sup>ab</sup>
4	AF+ prod. D	0.14±0.00 <sup>bc</sup>	0.09±0.00 <sup>ab</sup>	0.11±0.01 <sup>f</sup>
5	OT	0.12±0.01 <sup>cd</sup>	0.07±0.01 <sup>b</sup>	0.12±0.02 <sup>ef</sup>
6	OT+ prod. C	0.12±0.00 <sup>cd</sup>	0.08±0.00 <sup>b</sup>	0.12±0.02 <sup>ef</sup>
7	OT+ prod. D	0.11±0.01 <sup>d</sup>	0.09±0.00 <sup>ab</sup>	0.18±0.03 <sup>a</sup>
8	AF+OT	0.10±0.01 <sup>d</sup>	0.08±0.00 <sup>b</sup>	0.14±0.03 <sup>cd</sup>
9	AF+OT+ prod. C	0.10±0.01 <sup>d</sup>	0.07±0.00 <sup>b</sup>	0.14±0.01 <sup>cde</sup>
10	AF+OT+ prod. D	0.10±0.01 <sup>d</sup>	0.07±0.00 <sup>b</sup>	0.16±0.02 <sup>ab</sup>

“a, b & c”: There is significant difference (P<0.05) between any two means, within the same column have the different superscript letter. AMC in experiment (II): antimycotoxicosis compounds in drinking water of 2 weeks old chicks after appearance of signs \* Prod. C: combination of bacterial cell wall extract; oligosaccharides; L-form bacteria extract; group of mycotoxin biotransforming enzymes; organic acid and salts; hepatic and renal tonic; vitamins. \*\* Prod. D: formed from isomalto-oligosaccharide; micronized-mannan oligosaccharide; lactobacillus extract; cholestyramine

Table (9) the effect of investigated antimycotoxicosis compounds used as feed additives on histopathological lesions in the immune organs

Group	Treatment	Histopathological lesions in the immune organs of broiler chickens <sup>♦</sup>			
		1 <sup>st</sup> Week	2 <sup>nd</sup> Week	3 <sup>rd</sup> Week	Total score
1	Control (-ve)	0	0	0	0±0 <sup>d</sup>
2	AF	6	6	8	6.67±0.19 <sup>a</sup>
3	AF+ prod. A	3	3	6	4.56±0.4 <sup>b</sup>
4	AF+ prod. B	3	3	8	3.67±0.69 <sup>b</sup>
5	OT	5	5	7	4.2±0.4 <sup>b</sup>
6	OT+ prod. A	1	2	3	1.89±0.11 <sup>c</sup>
7	OT+ prod. B	4	4	6	3.67±0.51 <sup>c</sup>
8	AF+OT	7	7	9	5.89±0.22 <sup>a</sup>
9	AF+OT+ prod. A	2	2	6	1.67±0.19 <sup>c</sup>
10	AF+OT+ prod. B	3	3	6	2.4±0.29 <sup>c</sup>

“a, b & c”: There is significant difference (P<0.05) between any two means, within the same column have the different superscript letter. \*AMC in experiment (I): antimycotoxicosis compounds / starter feed from 1 to 21 day of chick age\* Prod. A: combination of *Eubacterium* BBSH<sup>797</sup> and *Trichosporonmycotxinivoran*; plant extract; algae extract. \*\* Prod. B: formed from nano-clay; seaweed extract; yeast cell wall; diatomaceous earth

Table (10) the effect of investigated antimycotoxicosis compounds used in drinking water on histopathological lesions scores in the immune organs

Group	Treatment	Histopathological lesions scores in the immune organs <sup>♦</sup>			
		1 <sup>st</sup> Week	2 <sup>nd</sup> Week	3 <sup>rd</sup> Week	Total score
1	Control (-ve)	0	0	0	0±0 <sup>f</sup>
2	AF	6	6	8	6.67±0.19 <sup>a</sup>
3	AF+ prod. C	6	5	0	5.78±0.29 <sup>ab</sup>
4	AF+ prod. D	5	7	0	5.67±0.19 <sup>b</sup>
5	OT	5	5	7	4.2±0.4 <sup>cd</sup>
6	OT+ prod. C	6	5	3	3.2±0.48 <sup>e</sup>
7	OT+ prod. D	4	5	2	3.67±0.38 <sup>de</sup>
8	AF+OT	7	7	9	5.89±0.22 <sup>ab</sup>
9	AF+OT+ prod. C	7	8	4	4.67±0.19 <sup>c</sup>
10	AF+OT+ prod. D	7	6	5	4.67±0.19 <sup>c</sup>

“a, b & c”: There is significant difference (P<0.05) between any two means, within the same column have the different superscript letter.

(♦) Lesion score of group: mean of all reported lesions in the immune organs of the same group.

1-3: Mild lesion score (1: +Mild lesion, 2:++ Mild lesion and 3: +++ Mild lesion).

4-6: Moderate lesion scores (4:+ Moderate lesion, 5:++ Moderate lesion and 6:+++ Moderate lesion).

7-9: Severe lesion scores (7: + Severe lesion, 8:++ Severe lesion and 9: +++ Severe lesion).

AMC in experiment (II): antimycotoxicosis compounds in drinking water of 2 weeks old chicks after appearance of signs \* Prod. C: combination of Bacterial cell wall extract; oligosaccharides; L-form bacteria extract; group of mycotoxin biotransforming enzymes; organic acid and salts; hepatic and renal tonic; vitamins. \*\* Prod. D: formed from isomalto-oligosaccharide; micronized-mannan oligosaccharide; *Lactobacillus* extract; cholestyramine



Efficacy of different antimycotoxigenic compounds

Table (11) the effect of investigated antimycotoxigenic compounds used as feed additives on ND antibody titers

Group	Treatment	ND antibody titres (Mean± SE)			
		Zero day	1 <sup>st</sup> Week	2 <sup>nd</sup> Week	3 <sup>rd</sup> Week
1	Control (-ve)		8.3±0.3 <sup>ab</sup>	7.3±0.3 <sup>a</sup>	6.3±0.3 <sup>a</sup>
2	AF		6.3±0.3 <sup>e</sup>	4.3±0.3 <sup>de</sup>	3±0.6 <sup>d</sup>
3	AF+ prod. A		7.7±0.7 <sup>c</sup>	6±0 <sup>b</sup>	3.7±0.33 <sup>c</sup>
4	AF+ prod. B		8.7±0.3 <sup>a</sup>	6±0 <sup>b</sup>	3.7±0.33 <sup>c</sup>
5	OT		7±0 <sup>d</sup>	4±0.6 <sup>e</sup>	3.7±0.33 <sup>c</sup>
6	OT+ prod. A	9.7±0.3 <sup>a</sup>	6.33±0.3 <sup>e</sup>	5±0 <sup>c</sup>	3.7±0.33 <sup>c</sup>
7	OT+ prod. B		6.7±0.3 <sup>de</sup>	6.3±0.3 <sup>b</sup>	4±0.58 <sup>c</sup>
8	AF+OT		8±0 <sup>bc</sup>	4±0.6 <sup>e</sup>	3±0 <sup>d</sup>
9	AF+OT+ prod. A		7.7±0.3 <sup>c</sup>	6±0 <sup>b</sup>	3±0.6 <sup>d</sup>
10	AF+OT+ prod. B		6.7±0.3 <sup>de</sup>	4.7±0.3 <sup>cd</sup>	5±0 <sup>b</sup>

“a, b & c”: There is significant difference (P<0.05) between any two means, within the same column have the different superscript letter. ♦♦ Antibody titers expressed as the log<sub>2</sub> of the reciprocal of the highest dilution in which Haemagglutination was observed macroscopically. AMC in experiment (I): antimycotoxigenic compounds / starter feed from 1 to 21 day of chick age\* Prod. A: combination of *Eubacterium* BBSH<sup>797</sup> and *Trichosporon mycotoxinivoran*; plant extract; algae extract. \*\* Prod. B: formed from nano-clay; seaweed extract; yeast cell wall; diatomaceous earth

Table (12) the effect of investigated antimycotoxigenic compounds used in drinking water on ND antibody titers

Group	Treatment	ND antibody titers (Mean± SE)			
		Zero day	1 <sup>st</sup> Week	2 <sup>nd</sup> Week	3 <sup>rd</sup> Week
1	Control (-ve)		8.3±0.33 <sup>a</sup>	7.33±0.33 <sup>a</sup>	6.33±0.33 <sup>a</sup>
2	AF		6.33±0.33 <sup>c</sup>	4.33±0.33 <sup>cd</sup>	3.00±0.58 <sup>c</sup>
3	AF+ prod. C		6.33±0.33 <sup>c</sup>	4.33±0.67 <sup>cd</sup>	3.00±0.00 <sup>c</sup>
4	AF+ prod. D		6.33±0.33 <sup>c</sup>	4.00±1.00 <sup>d</sup>	3.67±0.33 <sup>bc</sup>
5	OT		7.00±0.00 <sup>bc</sup>	4.00±0.58 <sup>d</sup>	3.67±0.33 <sup>bc</sup>
6	OT+ prod. C	9.7±0.3 <sup>a</sup>	7.00±0.58 <sup>bc</sup>	5.00±0.00 <sup>bc</sup>	3.67±0.33 <sup>bc</sup>
7	OT+ prod. D		7.00±0.0 <sup>bc</sup>	5.33±0.33 <sup>b</sup>	3.67±0.67 <sup>bc</sup>
8	AF+OT		8.00±0.0 <sup>a</sup>	4.00±0.58 <sup>d</sup>	3±0 <sup>c</sup>
9	AF+OT+ prod. C		7.67±0.67 <sup>ab</sup>	4.00±0.58 <sup>d</sup>	3.67±0.33 <sup>bc</sup>
10	AF+OT+ prod. D		8.00±0.58 <sup>a</sup>	4.33±1.33 <sup>cd</sup>	4.33±0.33 <sup>b</sup>

“a, b & c”: There is significant difference (P<0.05) between any two means, within the same column have the different superscript letter. AMC in experiment (II): antimycotoxigenic compounds in drinking water of 2 weeks old chicks after appearance of signs \* Prod. C: combination of bacterial cell wall extract; oligosaccharides; L-form bacteria extract; group of mycotoxin biotransforming enzymes; organic acid and salts; hepatic and renal tonic; vitamins. \*\* Prod. D: formed from isomalto-oligosaccharide; micronized-mannan-oligosaccharide; *lactobacillus* extract; cholestyramine

Table (13) the effect of investigated antimycotoxigenic compounds used as feed additives on IBD antibody titers

Group	Treatment	IBD antibody titers (Mean± SE)			
		Zero day	1 <sup>st</sup> Week	2 <sup>nd</sup> Week	3 <sup>rd</sup> Week
1	Control (-ve)		3485±88.46 <sup>a</sup>	1429±54.55 <sup>a</sup>	672±5.13 <sup>a</sup>
2	AF		2746±115.34 <sup>c</sup>	790±43.52 <sup>d</sup>	263±24.97 <sup>c</sup>
3	AF+ prod. A		3409±117.89 <sup>a</sup>	876±19.08 <sup>cd</sup>	615±24.19 <sup>a</sup>
4	AF+ prod. B		3080±258.29 <sup>b</sup>	946±11.06 <sup>bc</sup>	250±4.33 <sup>c</sup>
5	OT		1930±86.00 <sup>e</sup>	830±4.16 <sup>cd</sup>	112±4.33 <sup>d</sup>
6	OT+ prod. A	5712±77.7 <sup>a</sup>	1938±64.51 <sup>e</sup>	857±6.77 <sup>cd</sup>	155±17.84 <sup>cd</sup>
7	OT+ prod. B		1849±43.13 <sup>e</sup>	886±0.88 <sup>cd</sup>	160±16.83 <sup>cd</sup>
8	AF+OT		1594±57.71 <sup>f</sup>	716±23.18 <sup>d</sup>	172±18.82 <sup>cd</sup>
9	AF+OT+ prod. A		2283±137.6 <sup>d</sup>	890±20.17 <sup>cd</sup>	224±48.25 <sup>cd</sup>
10	AF+OT+ prod. B		2740±72.9 <sup>c</sup>	1039±64.84 <sup>b</sup>	452±23.47 <sup>b</sup>

“a, b & c”: There is significant difference (P<0.05) between any two means, within the same column have the different superscript letter. AMC in experiment (I): antimycotoxigenic compounds / starter feed from 1 to 21 day of chick age\* Prod. A: combination of *Eubacterium* BBSH<sup>797</sup> and *Trichosporon mycotoxinivoran*; plant extract; algae extract. \*\* Prod. B: formed from nano-clay; seaweed extract; yeast cell wall; diatomaceous earth

Table (14) the effect of investigated antimycotoxigenic compounds used in drinking water on IBD titers

Group	Treatment	IBD antibody titers (Mean± SE)			
		Zero day	1 <sup>st</sup> Week	2 <sup>nd</sup> Week	3 <sup>rd</sup> Week
1	Control (-ve)		3485±88.46 <sup>a</sup>	1429±54.55 <sup>a</sup>	672±5.13 <sup>a</sup>
2	AF		2746±115.34 <sup>b</sup>	790±43.52 <sup>c</sup>	263±24.97 <sup>c</sup>
3	AF+ prod. C		2612±166.77 <sup>b</sup>	754±35.69 <sup>c</sup>	327±14.00 <sup>b</sup>
4	AF+ prod. D		2627±726.33 <sup>b</sup>	755±32.63 <sup>c</sup>	271±8.50 <sup>c</sup>
5	OT		1930±86.00 <sup>c</sup>	830±4.16 <sup>b</sup>	112±4.33 <sup>d</sup>
6	OT+ prod. C	5712±77.7 <sup>a</sup>	1954±30.41 <sup>c</sup>	820±379 <sup>b</sup>	217±4.33 <sup>c</sup>
7	OT+ prod. D		1949±96.75 <sup>c</sup>	898±201.7 <sup>b</sup>	136±21.83 <sup>d</sup>
8	AF+OT		1594±57.71 <sup>d</sup>	716±23.18 <sup>c</sup>	172±18.82 <sup>cd</sup>
9	AF+OT+ prod. C		1712±198.22 <sup>cd</sup>	706±38.16 <sup>c</sup>	508±78.88 <sup>a</sup>
10	AF+OT+ prod. D		1654±112.98 <sup>d</sup>	687±37.17 <sup>c</sup>	311±9.87 <sup>b</sup>

“a, b & c”: There is significant difference (P<0.05) between any two means, within the same column have the different superscript letter. AMC in experiment (II): antimycotoxigenic compounds in drinking water of 2 weeks old chicks after appearance of signs \* Prod. C: combination of bacterial cell wall extract; oligosaccharides; L-form bacteria extract; group of mycotoxin biotransforming enzymes; organic acid and salts; hepatic and renal tonic; vitamins. \*\* Prod. D: formed from isomalto-oligosaccharide; micronized-mannan oligosaccharide; *Lactobacillus* extract; cholestyramine

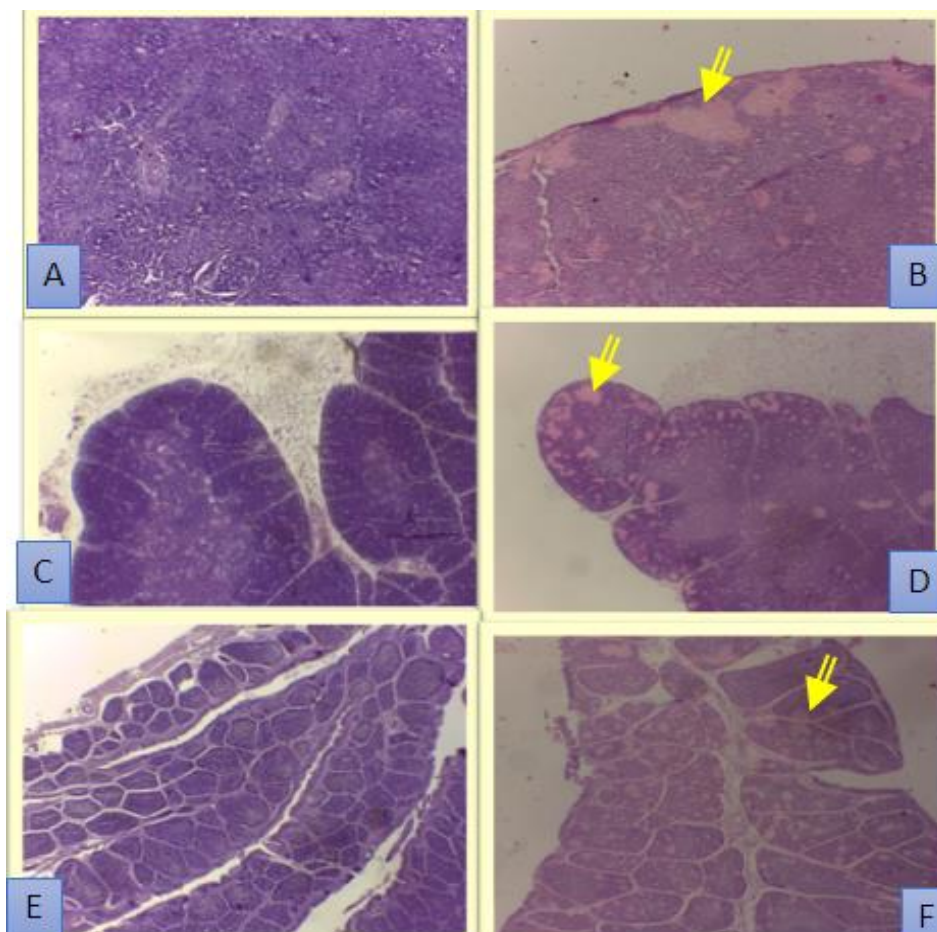


Plate (1): Histopathological lesions in the investigated immune organs of broiler chick. **A.** Spleen of control negative group showing normal white and red pulp (H&E; x 10). **B.** Spleen of chicks aged 21 days fed AF contaminated diet showing moderate multifocal necrosis (yellow arrows) (H&E; x 10). **C.** Thymus of chicks of control negative group showing normal lymphoid follicles (H&E; x10). **D.** Thymus of chicks aged 21 days fed OT contaminated diet showing moderate multifocal necrosis (yellow arrow) (H&E; x 4). **E.** Bursa of Fabricius in chicks of control negative group aged 14 days showing normal lymphoid follicles (H&E; x 4). **F.** Bursa of Fabricius in chicks aged 21 days fed AF and OT contaminated diet showing severe multifocal necrosis (yellow arrow) (H&E; x 4).

### 3.2. Histopathological lesions in the immune organs

Feeding of AF and/or OT to the broiler chickens produced microscopic changes in the immune organs with difference in their severity from mild to severe. Spleen, thymus and bursa of Fabricius in the chicks fed AF and/ OT contaminated diet showed multifocal areas of necrosis as illustrated in Plate 1.

Control positive group 8 reported the highest histopathological lesion scores in the immune organs as 23 followed by 20 in group 2 then 17 in-group 5 during the whole period of the experiments. These reported microscopic lesion scores in the tested immune organs were significantly ( $P$

$<0.05$ ) decreased with use of AMCs A or B in feed or treating with AMCs C or D in drinking water (Tables 9 & 10).

### 3.3. Humoral immune response against ND

Control positive groups 2, 5 and 8 showed significant ( $P < 0.05$ ) decrease in ND antibody titers when compared with control negative group. The use of AMC products A or B in feed reported significant ( $P < 0.05$ ) improvement in ND antibody titers of broiler chicks fed single contaminated diets with AF. In addition, the use of AMC B recorded significant ( $P < 0.05$ ) increase in ND antibody titers of the OT intoxicated broiler chicks (group 7) in comparison with control positive group

5. While the treatment of the AF and/or OT intoxicated broiler chicks with AMC (products C or D/ drinking water) showed non-significant ( $P > 0.05$ ) difference in ND antibody titers with control positive groups 2, 5 and 8 (Tables 11 and 12).

#### 3.4. Humoral immune response against IBD

Chicks in control positive groups 2, 5 and 8 showed significant ( $P < 0.05$ ) decrease in IBD antibody titers when compared with control negative group. The dietary supplementation of AMC products A or B to single OT or mixed AF and OT contaminated diets showed significant ( $P < 0.05$ ) increase in IBD antibody titers along the treatment period when compared with control positive groups 5 and 8. On contrary, the treatment of the AF and/or OT intoxicated chicks with AMC products C or D in drinking water reported non-significant ( $P > 0.05$ ) difference in IBD antibody titers with the intoxicated groups 2, 5 and 8 (Tables 13 & 14).

### 4. DISCUSSION

Antimycotoxicosis compounds A or B in feed, reported significant ( $P < 0.05$ ) increase in the relative weights of the tested immune organs when compared to control positive groups 2, 5 and 8 (Tables 3, 5 & 7). These findings came in partially agreement with the reports of Raju and Devegowda, (2002); Shi *et al.*, (2006) and (2009). Raju and Devegowda, (2002) who found that the addition of estrified glucomannan (0.1% feed) to AF (300 ppb) and/ or OT (2 ppm) diet significantly increase the relative weight of thymus in the broiler chicken. Also, Shi *et al.*, (2006) and (2009) reported that the addition of modified montmorillonite as 3 gm/kg feed to AF 0.1 mg/kg feed significantly ( $P < 0.05$ ) increase the relative weights of bursa of Fabricius and spleen in the broiler chicken. This could be attributed to the ability of AMCs feed additives' components to adsorb and/or biotransforming mycotoxin and lead to

decrease the absorption of mycotoxins from GIT and therefore reduce their toxicity (EFSA, 2009 and Devreese *et al.*, 2013).

In the 3<sup>rd</sup> week of experiment II, the use of AMC product D for the treatment of chicks in the groups 7 and 10 showed significant ( $P < 0.05$ ) increase in the thymus and spleen relative weights of chicks when compared with control positive groups 5 and 8 (Tables 4 & 6). Moreover, bursa of Fabricius, relative weight of birds reported significant ( $P < 0.05$ ) increase with the use of AMC product C for treating chicks intoxicated with AF (group 3) and product D in treating chicks of groups 7 & 10 (Table 8). Similarly, Shareef and Omar, (2012) found that the addition of a commercial antimycotoxicosis drug which contains the same components of product C in drinking water of broiler chicken was effective in counteracting the negative effect of AF regarding the relative weights the thymus, bursa of Fabricius and spleen. They suggested that the contents of this product (mixture of soluble enzymes, yeast extract and organic acids) played an important role as a chelating agent and the sequestration of AF through GIT.

Our study revealed that product D when used in the intoxicated chicks with OT single or when combined with AF reported significant ( $P < 0.05$ ) increase in the relative weight of bursa. These results may be related to the binding ability of cholestyramine (a main component of this product) to reduce OT concentration in the blood, bile, and tissues and our results are supported by the explanation of Huwig *et al.*, (2001); EFSA, (2009) and Devreese *et al.*, (2013).

In the present investigation, the relative weights of thymus, bursa of Fabricius, and spleen were significantly ( $P < 0.05$ ) decreased in the control positive groups (Tables 3-8). Similar observations were recorded by Ortatatli and Oguz, (2001); Raju and Devegowda, (2002); Stoev *et al.*, (2002); Shareef and Omar, (2012); Indresh and Umakantha, (2013) and Peng *et al.*,

(2015). The reduction in size of lymphoid organs (bursa, thymus and spleen) might have been due to necrosis and cellular depletion by the mycotoxins (Ortatatli and Oguz, 2001 and Indresh and Umakantha, 2013). Moreover, feeding of AF and/ or OT contaminated diet to the broiler chickens in the current study produced microscopic changes in th

e immune organs with difference in their severity from mild to severe as shown in Plates(1-3). These findings were the confirmative tools for occurrence of atrophy and lymphoid depletion due to mycotoxins that previously reported in the current investigation as decrease in the relative weight of the immune organs of broiler chickens. Similar microscopic lesions of immune organs associated with AF were recorded by Ortatatli and Oguz, (2001) and Peng *et al.*, (2015). Peng *et al.*, (2015) who stated that thymus, bursa and spleen were target organs in chicks fed naturally contaminated corn with AFB<sub>1</sub> and AFB<sub>2</sub>. Moreover, Santin *et al.*,(2002); Stoevet *al.*, (2002); Elaroussi *et al.*,(2006); Hanif *et al.*, (2008); Xue *et al.*, (2010) recorded nearly similar microscopic lesions in the immune organs of the ochratoxicated broiler chickens. It is generally accepted that the degenerative and necrotic changes of the immune organs provoked by direct cytotoxic effects of mycotoxins and it is a result of apoptosis (Al-Anati and Petzinger, 2006 and Peng *et al.*, 2017).

With positive view, the histopathological lesion scores in the immune organs were significantly ( $P < 0.05$ ) decreased with use of AMC products A, B, C or D (Tables 9 - 10). Our findings are in accordance with the results of Ortatatli and Oguz, (2001) who reported less histopathological changes in the immune organs of OT intoxicated broiler chickens fed diet treated with clinoptilolite; Santin *et al.*,(2002) who fed broilers mixtures supplemented with 2 mg/kg of OTA and 0.25% of aluminosilicate. Similarly, Hanif *et al.*, (2008) and Xue *et al.*, (2010) showed less

pronounced microscopic lesions in the immune organs of the OT intoxicated broiler chickens with dietary supplementation of a commercial mycotoxin deactivator containing *Trichosporon mycotoxinivoran*.

Prophylactic immunization against ND and IBD is vital to safeguard against these infectious diseases in broiler chickens (Oguz *et al.*, 2003). AF and OT either individually or in combination, are immuno-suppressant (Verma *et al.*, 2004). Determination of ND and IBD antibody titers to the corresponding viruses after regular vaccination used to evaluate the efficacy of antimycotoxin detoxifying agents on the immune system of broiler chickens fed mycotoxin-contaminated diets (EFSA, 2009). The addition of AMC product A or B into the contaminated diets with AF or OT improve significantly ( $P < 0.05$ ) the antibody titers against ND and IBD vaccination (Tables 11&13). These results were came in accordance with Hanif and Muhammad, (2015) who showed that a commercial mycotoxin deactivator containing *Trichosporon mycotoxinivoran* was capable of counteracting the deleterious effects of OT on humoral immune response of chicks against ND. Similarly, use of yeast cell wall extract in broiler chicken showed effective immune-modulation action against aflatoxicosis (Raju and Devegowda, 2002; Ghahri *et al.*, 2010; Abd El-Ghany *et al.*, 2013; Bhatti *et al.*, 2017 and Mohaghegh *et al.*, 2017) and ochratoxicosis (Raju and Devegowda, 2002; Awaad *et al.*, 2011 and Mohaghegh *et al.*, 2017). Moreover, addition of dietary mycotoxin binders, as sodium bentonite, clinoptilolite and HSCAS, were effective in ameliorating the suppressive effect of AF or OT on the humoral immunity (Ibrahim *et al.*, 2000, Oguz *et al.*, 2003; Ghahriet *al.*, 2010; Abd El-Ghany *et al.*, 2013 and Bhatti *et al.*, 2017). The efficacy of AMC product A or B to ameliorate the negative effects of mycotoxins on humoral immune response may be related to their

contents from antimycotoxin detoxifying agents (EFSA, 2009) in addition to yeast cell wall extract that had a potent immunomodulatory effect, evoked immune response and enhanced vaccination effectiveness (Awaad et al., 2011).

In experiment II, the use of AMCs C or D in drinking water did not have any beneficial effects against the negative effects of AF and/or OT on the humoral immune response of ND and IBD vaccination (Tables 12&14). These findings were in disagreement with Shareef and Omar (2012) who found a significant increase in antibody titer against ND of the AF intoxicated broiler chickens with the use of a commercial mycotoxin-detoxifying product (contain the same component of product C). This may be due to the difference in duration of drug administration in addition to exposure period, dose and type of mycotoxin.

The AF and/or OT intoxicated chicks in control positive groups 2, 5 and 8 showed significant ( $P<0.05$ ) decrease in ND and IBD antibody titers when compared with the negative control group (Tables 11-14). The reduction in the antibody titers was in agreement with several previous reports of Ibrahim et al., (2000); Raju and Devegowda, (2002); Oguz et al.,(2003); Verma et al., (2004); Ghahri et al., (2010); Abd El-Ghany et al., (2013); Bhatti et al.,(2017) and Mohaghegh et al.,(2017) who used dietary inclusion of AF in broiler chicken. Similarly, Raju and Devegowda, (2002); Santin et al.,(2002); Verma et al., (2004); El Aroussi et al.,(2006) & (2008) ; Xue et al., (2010); Awaad et al., (2011); Indresh and Umakantha, (2013); Hanif and Muhammad, 2015; Bhatti et al.,(2017) and Mohaghegh et al.,(2017) recorded the same results in chicks fed OT contaminated diets. The reported depression in ND and IBD antibody titer values in the present study is a clear indication for the immunosuppressive effect. It is generally accepted that the degenerative and necrotic changes of the immune organs provoked by direct cytotoxic effects of mycotoxins

(Surai and Mezes, 2005; Al-Anati and Petzinger, 2006 and Peng et al., 2017). In addition to, AF and OT inhibit DNA and protein synthesis resulting in decrease antibody production (Oguz et al., 2003; Indresh and Umakantha, 2013).

## CONCLUSION

This study has shown that the dietary supplementation of AMCs, reduced ( $P<0.05$ ) significantly the adverse effects of AF and/or OT on the tested immune organs and humoral immune response against ND and IBD vaccination in the intoxicated broilers. On contrary, the treatment of the intoxicated broiler chicks with AMCs products C or D in the drinking water showed partially and temporarily improvement in the relative weights and the histopathological lesion scores of the tested immune organs and did not improve the negative effects of AF and/or OT on the antibody titers against ND and IBD vaccination.

## ACKNOWLEDGMENT

This work would not have been possible without the financial support of Scientific research Fund (SRF), Benha university

## 5. REFERENCES

- Abd El-Ghany, W.; Hatem, M.E.; Ismail M. (2013): Evaluation of the efficacy of feed additives to counteract the toxic effects of aflatoxicosis in broiler chickens. *International Journal Animal and Veterinary Advances* 5: 171-182.
- Al-Anati, L.; Petzinger, E. (2006): Immunotoxic activity of ochratoxin A. *J. Vet. Pharmacol. Ther.* 29, 79–90.
- Awaad, M. H. H.; Atta, A.M.; Abd El-Ghany, W. A.; Elmenaway, M.; Ahmed, K.; Hassan, A. A.; Nada, A. A.; Abdelaleem, G. A. (2011): Effect of a specific combination of mannan-oligosaccharides and  $\beta$ -glucans extracted from yeast cell wall on the health status and growth

- performance of ochratoxicated broiler chickens. *Journal of American Science*, 7:82-9.
- Bennett, J. W.; Klich, M., (2003): Mycotoxins. *Clin. Microbiol. Rev.* 16, 497–516.
- Bhatti, S. A.; Khan, M. Z.; Saleemi, M.K.; Saqib, M.; Khan A. ; El-Hassan, Z. (2017): Protective role of bentonite against aflatoxin B1- and ochratoxin A-induced immunotoxicity in broilers, *Journal of Immunotoxicology*, DOI:10.1080/1547691X.2016.1264503.
- Council for Agricultural Science and Technology (CAST, 2003): Mycotoxins: risks in plants, animal and human systems. Task force report No. 139, Ames, Iowa, USA, 99.
- Devreese, M.; Backer, P. and Croubels, S. (2013): Different methods to counteract mycotoxin production and its impact on animal health. *Vlaams Diergeneeskundig Tijdschrift*, 82, 181-190.
- Duncan, D. B. (1955): New multiple range and multiple F test. *Biometrics*, 11:1-42.
- El aroussi, M. A.; Mohamed, F. R.; El Barkouky, E. M.; Atta, A. M.; Abdoul, A.M. ; Hatab, M. H. (2006): Experimental ochratoxicosis in broiler chickens. *Avian Path*, 35: 263-269.
- El aroussi, M.A.; Mohamed, A.; Elgandy, M. S.; El Barkouky, E. M.; Abdoul, A.M. and Hatab, M. H. (2008): Ochratoxicosis in broiler chickens: functional and histological changes in target organs. *International Journal of Poultry Science*, 7 (5): 414-422.
- El Nabarawy, A. M.; Madian, K.; Aly, E. ; Madbouly, Y. (2016): The effect of mycotoxins on immune response of broilers to the live ND vaccines applied by different routes. *Middle East J. of Applied Sciences*, 6 (1):51-58.
- European feed safety agency (EFSA, 2009): Review of mycotoxin-detoxifying agents used as feed additives: mode of action, efficacy and feed/food safety. <http://www.efsa.europa.eu/en/supporting/pub/22e.htm>.
- Ghahri, H.; Habibian, R.; Fam, M. A. (2010): Evaluation of the efficacy of esterified glucomannan, sodium bentonite, and humic acid to ameliorate the toxic effects of aflatoxin in broilers. *Turkish Journal of Veterinary and Animal Sciences*, 34, 385–391.
- Hanif, N. Q.; Muhammad, G. (2015): Immunotoxicity of ochratoxin A and role of *Trichosporon mycotoxinivorans* on the humoral response to infectious viral disease vaccines in broilers. *Pakistan J. Zool.*, 47(6), 1683-1689.
- Hanif, N. Q.; Muhammad, G.; Siddique, M.; Khanum, A.; Ahmed T; Gadahai, J. A. ; Kaukab, G. (2008): Clinico-patho-morphological, serum biochemical and histological studies in broilers fed ochratoxin A and a toxin deactivator (Mycofix Plus). *Br. Poult. Sci.*, 49:632-42.
- Hussain, Z. (2006): Aflatoxicosis in chicken: an inter-relationship between pathology dietary and tissue aflatoxin levels. PhD degree thesis, Faculty of Veterinary science, University of agriculture Faisalabad Pakistan.
- Huwig, A.; Freimund, S.; Kappeli, O.; Dutler, H. (2001): Mycotoxin detoxification of animal feed by different adsorbents. *Toxicological Letter*; 122, 179–188.

- Ibrahim, I. K.; Shareef, A. M. ; Joubory, K. M. T. (2000): Ameliorative effects of sodium bentonite on phagocytosis and Newcastle disease antibody formation in broiler chickens during aflatoxicosis. *Res. Vet. Sci.*, 69(2): 119-122.
- Indresh, H. C.; Umakantha, B. (2013): Effects of ochratoxin and T-2 toxin combination on performance, biochemical and immune status of commercial broilers, *Veterinary World* 6(11): 945-949.
- Mohaghegh, A.; Chamani, M.; Shivazad, M.; Sadeghi, A. A. and Afzali, N. (2017): Effect of esterified glucomannan on broilers exposed to natural mycotoxin-contaminated diets, *Journal of Applied Animal research*, 45:1,285-291, DOI: 10.1080/09712119.2016.1174122.
- Oguz, H.; Hadimli, H. H.; Kurtoglu, V. and Erganis, O. (2003): Evaluation of humoral immunity of broilers during chronic aflatoxin (50 and 100 ppb) and clinoptilolite exposure. *Revue de Medicine Veterinaire*, 154: 483-486.
- OIE, (2012): *Terrestrial Manual*. Chapter 2. 3.14. Newcastle Disease, 13.
- Ortatatli, M. and Oguz, H. (2001): Ameliorative effects of dietary clinoptilolite on pathological changes in broiler chickens during aflatoxicosis. *Research in Veterinary Science*, 71, 59-66.
- Peng, X.; Bai, S.; Ding, X.; Zhang, K. (2017): Pathological impairment, cell cycle arrest and apoptosis of thymus and bursa of fabricius induced by aflatoxin-contaminated corn in broilers. *Int. J. Environ. Res. Public Health*, 14, 77
- Peng, X.; Shiping, B.; Xuemei, D.; Qiufeng, Z.; Keying, Z. and Jing, F. (2015): Pathological changes in the immune organs of broiler chickens fed on corn naturally contaminated with aflatoxins B<sub>1</sub> and B<sub>2</sub>. *Avian Pathology*, 44:3, 192-199.
- Raju, M. V.; Devegowda, G. (2002): Esterified-glucomannan in broiler chicken diets-contaminated with aflatoxin, ochratoxin and T-2 toxin: Evaluation of its binding ability (in vitro) and efficacy as immunomodulator. *Asian-Aust. J. Anim. Sci.*; 15 (7): 1051-1056.
- Resanovic, R. M.; Nešic, K. D.; Nestic, V. D.; Palic, T. D. and Jacevic, V. M. (2009): Mycotoxins in poultry production. *Proc. Nat. Sci, Matica Srpska Novi Sad*, 116:7-14.2009.
- Ringot, D.; Chango, A.; Schneider, Y. J. and Larondelle, Y. (2006): Toxicokinetics and toxicodynamics of ochratoxin A, an update. *Chem. Biol. Interact.*, 159: 18-46.
- Santin, E.; Paulillo, A. C.; Maiorka, P. C.; Alessi, A. C.; Krabbe, E. L. and Maiorka, A. (2002): The effects of ochratoxin/aluminosilicate interaction on the tissues and humoral immune response of broilers', *Avian Pathology*, 31: 1, 73-79.
- Scheur, P.J. and Chalk, B.T. (1986): *Clinical tests: Histopathology*, (London, and Wolfe Medical Publications).
- Shareef, A. M.; Omar, E. K. S. (2012): Effect of Synertox<sup>®</sup> on broiler health and performance during aflatoxicosis. *Iraqi Journal of Veterinary Sciences*, 26 (II): 27-34.
- Shi, Y.; Xu, Z.; Feng, J. and Wang C. (2006): Efficacy of modified montmorillonite nanocomposite to reduce the toxicity of aflatoxin in broiler chicks. *Animal Feed Science and Technology* 129; 138-148.
- Shi, Y.; Xu, Z.; Sun, Y.; Wang, C. and Feng, J. (2009): Effects of two different types of montmorillonite on



- growth performance and serum profiles of broiler chicks during aflatoxicosis. Turkish journal of veterinary and animal science, 33: 15–20.
- Shotwell, O. L.; Hesslone, C. W.; Staublefield, R. D.; Soreson, W. G. (1966): Production of aflatoxins on rice. Appl. Microbial. 14:425-42.
- Stoev, S. D.; Daskalov, H.; Radic, B.; Domijan, A. and Peraica, M. (2002): Spontaneous mycotoxic nephropathy in Bulgarian chickens with unclarified mycotoxin aetiology. Vet. Res; 33, 83–94.
- Surai, P. F.; Mezes, M. (2005): Mycotoxins and immunity: Theoretical consideration and practical applications. Praxis Veterinaria, 53: 71-88.
- Trenk, H. L.; Butz, M. E.; Chu, F. S. (1971): Production of ochratoxins in different cereal products by *Aspergillus ochraceus*. Applied microbiology, 1032-1035.
- Verma, J.; Johri, T. S.; Swain, B. K.; Ameena, S. (2004): Effect of graded levels of aflatoxin, ochratoxin and their combinations on the performance and immune response of broilers. British poultry science, 45: 512-518.
- Xue, C. Y.; Wang, G. H.; Chen, F.; Zhang, X. B.; Bi, Y. Z. ; Cao, Y. C. (2010): Immunopathological effects of ochratoxin A and T-2 toxin combination on broilers. Poultry Science; 89:1162–1166.