



## Dual effect of *Aspergillus Fumigatus* and *E. coli* O125 in broilers

Ibrahiem, M. El-Boroaay<sup>1</sup>, Samer, M. Abd El Kader<sup>1</sup>, and Adel, A. Shaheen<sup>2</sup>

<sup>1</sup>Department of Poultry Diseases, Faculty of Veterinary Medicine, Benha University.

<sup>2</sup>Department of Fish Diseases and management, faculty of Veterinary Medicine, Benha University.

### ABSTRACT

This study was conducted on 88 broiler chicks from one day to five days. They were collected from three hatcheries at two governorates to detect the prevalence of infection by *Aspergillus spp* and/or *E. coli* serotypes. This study revealed that the prevalence was 35.2%, 43.2% and 18.2% for *E. coli* serotypes, *Aspergillus spp* and both infection together, respectively. The clinical signs of the examined broiler chicks appeared as weakness, respiratory manifestation (gaspings) and diarrhea. The postmortem lesions were mainly on lungs and air sacs which appeared congestion, white nodules in lungs and yellowish white cheesy materials on air sacs and lungs. Some chicks showed signs of enteritis. Bacteriological and mycological examinations for collected broiler chicks revealed that *E. coli* O125 and *Aspergillus fumigatus* were the most common isolates. Experimental infection of 124 one-day old broiler chicks which checked and confirmed to be free from both infectious agents with inoculation of *E. coli* O125 (intranasal/ one dose) and/or *Aspergillus fumigatus* (intra air sacs/one dose) showed weakness, respiratory manifestation (gaspings), diarrhea, congested lungs and cheesy materials on lungs and air sacs. Reisolation and identification revealed positive results for infectious agents. Histopathological examination was also described. Concerning to growth performance and mortality rate, dual infection showed much decrease in weight and increase in mortality rate than single infection. In conclusion the dual infection has more pathogenic effect than single infection.

**Keywords:** *Aspergillus fumigatus*, *E. coli*, broilers, intranasal and intra air sacs inoculation.

(<http://www.bvmj.bu.edu.eg>)

(BVMJ-30(1): 283-294, 2016)

### 1. INTRODUCTION

Avian colibacillosis is an infectious disease of birds caused by *Escherichia coli*, which is considered either primary pathogen or a secondary pathogen. Colibacillosis is one of the principal causes of mortality and morbidity in chickens and turkeys resulting in significant economic losses in poultry industry, which translates into multimillion-dollar annual losses for all facets of the world's poultry industry (Barnes et al., 2008). The pathogenicity of *E. coli* for chicken has been correlated with numerous extrinsic and intrinsic bird-related factors and conditions. The extrinsic factors include environment, exposure to other infectious agents, virulence, levels and duration of exposure. The intrinsic factors

affecting susceptibility includes age, route of exposure, active and passive immune status and breed of chickens. (Piercy and West, 1976). Pulmonary aspergillosis is the most common form of the disease in avian species and is seen most frequently in young broiler chicken, turkey poults, young, mature and breeder turkey (Pier & Richard, 1992). Distribution of aspergillosis across the United States lead to mortality losses from the disease results in financial losses of more than 11 million dollars yearly, however, losses from carcass condemnation typically for outstrip mortality losses (Bounel and Imerman, 2000).

### 2. MATERIAL AND METHODS

## 2.1. Collection of chicks

### 2.1.1. Collection of examined broiler chicks:

A total of 88 one day old Hubbard chicks were collected from three different hatcheries (Al-Salheen Company at Al-Mansoura- Rommana Company at Gamasa and Ommat Company at Wadi El-natroon), some of them were dead and the others were life both dead and life chicks were transported to the lab of poultry diseases department –faculty of veterinary medicine- Benha university. Clinical examination, postmortem examination, bacteriological and mycological investigation were carried out for the dead and condemned ones from one to five days. Each bird was examined individually with a certain serial number.

### 2.1.2. Collection of chicks for experimentally infection with *E.coli* and/or *Aspergillus*:

A total of 124 one day old Hubbard chicks free from *E.coli* and *Aspergillus spp* were purchased from Al-Dakahlia Poultry Company (four random chicks were taken to insure their freedom from infectious agents) and the other chicks were experimentally infected with the well identified strains of *E.coli*(O125) and *Aspergillus (aspergillus fumigatus)*.

## 2.2. Bacteriological examinations:

One piece of lung from each chicks was taken and inoculated in nutrient broth for 24 hrs at 37°C then one drop was taken to culture on MacConkey agar for 24hrs at 37°C. One positive colony was taken to culture on Eosinmethylene blue agar (E.M.B) for 24hrs at 37°C under complete aseptic conditions. The positive cases were subjected to biochemical and serological tests at animal health researches institute at Dokki – Giza.

## 2.3. Mycological examinations:

One piece of lung from each chicks was taken, then cultured on subouraud dextrose agar for 5-7 days at 37°C under aseptic condition. One swab was taken from

positive colony to investigate the presence of *Aspergillus spp* under microscope.

## 2.4. Preparation of infectious agents for experimental infection:

### 2.4.1. Preparation of bacterial isolates for inoculation:

*E. coli* O125 was identified by (Animal health research institute at Al-Dokki– Giza), and prepared as 0.5ml inoculums containing 10<sup>8</sup> CFU of *E.coli* O125 the bacterial counting was applied through 0.5 (1.5×10<sup>8</sup>) McFarland standard for *E.coli*(Martin and Palomino, 2009) then applied infection by intranasal inoculation.

### 2.4.2. Preparation of *Aspergillus fumigatus* for inoculation:

The organism was routinely maintained on sabouraud dextrose agar plates supplemented with chloramphenicol (0.5gm/L), to obtain asexual spores (conidia), cultures were grown on yeast malt agar (0.3% yeast extract, 0.3% malt extract, 0.5% peptone, and 0.5% agar) at 37°C, after 3 days growth, a large number of conidia was produced, The conidia were harvested by flooding the plates with sterile distilled water. They were then pelleted by centrifugation, washed in phosphate buffer saline (0.15m) and quantified using a malassez cell. The chick was inoculated by transcutaneous injection into the right caudal thoracic air sac, the dose of infection was 100 µl spore suspension of a 3 day-old *A.fumigatus* culture containing 10<sup>7</sup> spores (Francoisefemina et al 2007)

## 2.5. Experimental design:

A total of 124 one day old chicks were used to study the pathogenicity of *E.coli* O125 and *Aspergillus fumigatus* (A.f). [Before infection, four chicks were taken randomly and sacrificed and subjected to bacteriological & mycological examination to prove their freedom from any *Aspergillus* or *E.coli* infection]. The remaining chick divided into 4 groups, each group include 30 chicks:

1-The first group considered as control group. 2-The second group infected by *E.coli* O125 at one day old. 3-The third group infected by *Aspergillus fumigatus* at one day old. 4-The fourth group infected by *E.coli* O125 and *Aspergillus fumigatus* at one day old. Then these chicks were monitoring for three weeks.

### 3. 3. RESULTS

#### 3.1. Results of collected broiler chicks:

##### 3.1.1. Clinical signs and postmortem examination:

At this study from 88 collected broiler chicks there were 14 chicks (15.9%) showed gasping, 56 chicks (63.63%) showed congested lungs fig. (1), 12 chicks (13.63%) showed cheesy materials on lungs and/or air sacs fig. (2), and 4 chicks (4.54%) showed white nodules on lungs fig. (3).

##### 3.1.2. Microbial examinations:

At present study from 88 collected chicks there are 35 chicks (39.77%) were free from *E. coli* and *Aspergillus* and 53 chicks (60.22%) have *E.coli* and/or *Aspergillus* and from these 53 chicks there were 15 chicks have *E.coli* only and 22 chicks have *Aspergillus* only fig. (4),(5) and 16 chicks have mixed infection by *E.coli* and *Aspergillus* by ratio(28.3%),(41.5%) and (30.18%), respectively.

##### 3.1.3. Relation between clinico-pathological lesions and isolated microorganism:

In the present study, from 14 chicks showed gasping (15.9%) there are 6 chicks have only *Aspergillus* infection (42.85%) and 2 chicks have only *E. coli* infection (14.28%) and 6 chicks have mixed infection by *E. coli* and *Aspergillus* (42.85%), table (1). From 56 chicks showed congested lungs (63.63%) there are 12 chicks have *Aspergillus* only (21.42%) and 9 chicks have *E. coli* only (13.84%) and 15 chicks have mixed infection by *E. coli* and *Aspergillus* (26.78%) and 20 chicks (35.7%) have no infection by *E. coli* or

*Aspergillus*, table (1). From 12 chicks showed cheesy material on lungs or airsacs (13.63%), there are 2 chicks have *Aspergillus* only (16.66%) and 3 chicks have *E. coli* only (25%) and 3 chicks have mixed infection by *E. coli* and *Aspergillus* (25%) and 4 chicks have no infection by *Aspergillus* or *E. coli* (33.33%), table (1). And from 4 chicks showed white nodules on lungs (4.54%) there are 3 chicks (75%) have infection by *Aspergillus* only and one chick (25%) have mixed infection by *E. coli* and *Aspergillus*, table (1). From the fore mentioned data there was outstanding role of *Aspergillus* spp and/or *E. coli* in the respiratory manifestation in the baby chicks. On the other hand, from 22 chicks have no clinical signs or P.M lesions (25%) there are 3 chicks have infection by *Aspergillus* only (13.63%) and 6 chicks have infection by *E. coli* only (27.27%) and one chick have mixed infection by *E. coli* and *Aspergillus* (0.04%) and 12 chicks have no infection by *E. coli* or *Aspergillus* (54.54%) as appear in table (1). Results of mycological identification and serological tests for bacterial isolates revealed that, *Aspergillus fumigatus* and *E. coli* O125 was most common isolates.

#### 3.2. Result of experimentally infected one day old broiler chicks:

##### 3.2.1. Clinical signs and postmortem examination:

These chicks showed weakness, respiratory manifestation (gasping), diarrhea, congested lungs and cheesy materials on lungs and air sacs.

##### 3.2.2. Mortality

The mortality of these groups recorded at table (2) which appear that: *Group 1*: no mortality until the end of experiment. *Group 2*: showed mortality 4 birds (13.3%) at first week and one bird (3.3%) at second week and 3 birds (10%) at third week and total mortality 8 birds (26.6%). *Group 3*: showed mortality 3 birds (10%) at first week and one bird (3.3%) at second week

and one bird (3.3%) at third week and total mortality 5 birds (16.6%).

*Group 4:* showed mortality 2 birds (6.6%) at first week and 3 birds (10%) at second week and 6 birds (20%) at third week and total mortality 11 birds (36.6%).

### 3.2.3. Growth performance:

Infection by *E.coli* O125 and *Aspergillus Fumigatus* have more bad effect on body weight followed by infection by *E.coli* O125 then infection by *Aspergillus Fumigatus*.

### 3.2.4. Histopathological examination:

*E.coli* O125 cause congested blood vessels and thrombus formation, granuloma and microgranulomas formation that found in lung tissues. Marked dilatation of secondary bronchiole with hyperplasia of lining epith. Focal clusters of intra lesional bacteria were observed in granuloma and in blood vessels. Submucosal hemorrhage and edema and fibrinopurulent exudates. Fig (6, 7, 8). *Aspergillusfumigatus* caused congestion of pulmonary blood vessels with thickening of its wall associated with perivascular edema fig (9). Dual infection caused nearly the same previous lesions but more severe than single infection fig (10, 11). This study revealed that, severity at histopathological lesions was more at dual infection, followed by *E.coli* O125 infection, then *Aspergillus fumigatus* infection.

## 4. DISCUSSION

In this study, we found that 15.9% from collected chicks were showed gasping, this result agree with Sajid et al., (2006), Chen et al., (2012), and Musa et al., (2014), and 63.63% from those chicks were showed congested lungs, 13.63% were showed cheesy materials on lungs and/ or air sacs, this result agree with Dwars et al (2009) and Abusalab(2010); also we found 4.54% of these chicks were showed white nodules on lungs, this result agree with EL Batrawy (1980) and Abdel Hameed and Hassieb(1987) .

In this study it was appear that, the percentage of *E. coli* isolation in collected broiler chicks reached about 35%. This result agrees with that reported by Verma and Adlakha (1971) and Ghosh (1987) who isolated *E. coli* from chicks by ratio 30.08% and 37%, respectively. But this result was higher than that of Javed et al., (1991) who reported the prevalence of *E. coli* in broilers was (10.53) at age from 3 to 6 weeks and (6.9%) in chicken of more than 6 weeks. On the other hand our results were lower than that reported by Arora et al. (1987) who isolated *E. coli* from chicks collected from farms by ratio 88.5%. The difference between these results and our result may have attributed to the difference of age of chick and difference in hygienic measures between farms and hatcheries. In concerning with the serological identification of *E. coli* isolates, it was found that, the *E. coli* were sub-grouped into O125, O114, O146 and O55 with percentage of 60%, 20%, 10% and 10% respectively. This result partially agree with Abd El-Galil et al. (1983) who found the most prevalent pathogenic serotypes were O125, O55, O119 and O78. Also our result partially agree with Ibrahim et al., (1998) who demonstrated a predominance of *E. coli* serotypes O125, O114, O78 and O158.

On the other hand, our result disagree with Gross (1994), Blanco et al. (1998) and Ewers et al. (2004) who recorded that, the most prevalent pathogenic avian *E. coli* serogroups at their countries was O5, O6, O9, O11, O25, O53, O51 and O109 these variation reflect that *E. coli* serogroups are country specific. on aspect of clinical signs, this study appeared that, chicks infected by *E. coli* either naturally or experimentally showed weakness, lazy chicks, decrease feed intake from first day postinfection. This result agree with that of Raji et al. (2003) and Dhelly et al. (2011) while Khalid (1990) observed mortality in chicks within 48 hrs without any clinical sings in one day old chicks inoculated with *E. coli* per os route. This difference may be attributed to difference in route of

Table (1): the relation between isolates and clinical signs or P.M lesions

Sign or P.M lesion	Total no. of chicks showed sign or P.M lesion	No. of chicks have E. coli	No. of chicks have Aspergillus	No. of chicks have mixed infection by E. coli and Aspergillus	No. of chicks have E. coli only	No. of chicks have Aspergillus only	No. of chicks have no Aspergillus or E. coli infection
Gasping	14 (15.9%)*	8 (57.14%)**	12 (85.7%)**	6 (42.85%)**	2 (14.28%)**	6 (42.85%)**	Zero (zero %)**
Congested lungs	56 (63.63%)*	24 (42.85%)**	27 (48.2%)**	15 (26.78%)**	9 (16.07%)**	12 (21.42%)**	20 (35.7%)**
Cheesy material on lungs or air sacs	12 (13.63%)*	6 (50%)**	5 (41.66%)**	3 (25%)**	3 (25%)**	2 (16.66%)**	4 (33.33%)**
White nodules on lungs	4 (4.54%)*	1 (25%)**	4 (100%)**	1 (25%)**	Zero (zero%)**	3 (75%)**	Zero (zero %)**
No signs and normal P.M examination	22 (25%)*	7 (31.8%)**	4 (18.18%)**	1 (4.54%)**	6 (27.27%)**	3 (13.63%)**	12 (54.54%)**

\* Ratio to total number of chicks (88 chicks).

\*\* Ratio to total number of chicks that showed this sign or P.M lesion.

Table 2 (Number of mortalities)

Group 4	Group 3	Group 2	Group 1	Age	Date
				0	14/1/2015
	2			1	15/1/2015
	1	2		2	16/1/2015
				3	17/1/2015
2		2		4	18/1/2015
				5	19/1/2015
				6	20/1/2015
				7	21/1/2015
2 (6.6%)	3 (10%)	4 (13.3%)	Zero		Total weekly mortalities
		1		8	22/1/2015
				9	23/1/2015
				10	24/1/2015
	1			11	25/1/2015
2				12	26/1/2015
1				13	27/1/2015
				14	28/1/2015
3 (10%)	1 (3.3%)	1 (3.3%)	Zero		Total weekly mortalities
2				15	29/1/2015
1	1			16	30/1/2015
1		2		17	31/1/2015
				18	1/2/2015
				19	2/2/2015
1		1		20	3/2/2015
1				21	4/2/2015
6 (20%)	1 (3.3%)	3 (10%)	Zero		Total weekly mortalities
11 36.6%	5 16.6%	8 26.6%	Zero		Total mortalities at experiment

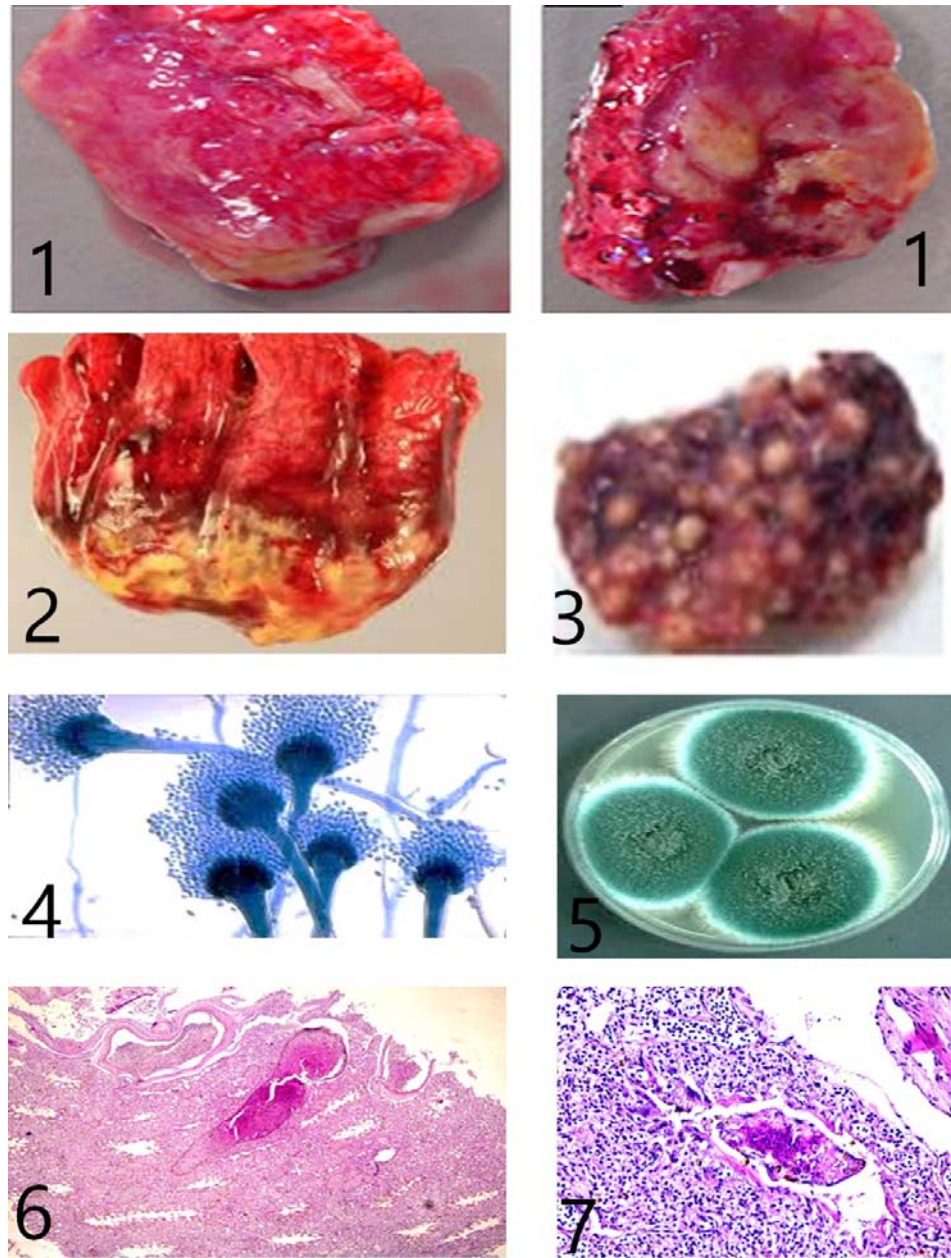


Fig (1) Difference degrees of congestion at lungs affected by *E. coli* and/or *Aspergillus* spp. Fig (2) cheesy materials on lung. Fig. (3) White nodules in lung affected by *Aspergillus* spp. Fig (4) *Aspergillus Fumigatus*. Fig (5) Colonies of *Aspergillus Fumigatus*. Fig (6): severe hyperemic pulmonary blood vessels. with marked thrombus formation in lung affected with *E. coli* O125. Fig (7): very obvious microgranulomas in parabrachial lumen of lung affected with *E. coli* O125

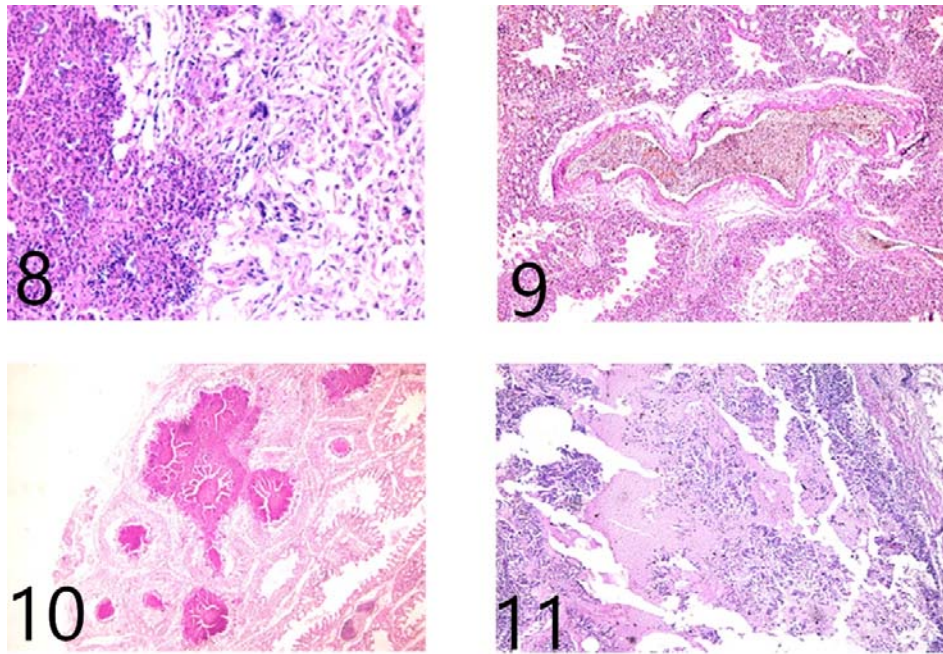


Fig (8): focal clusters of intralésional bacteria found in granuloma and in blood vessels in lung affected with *E.coli* O125. Fig (9): thickening and edema of the epithelial lining blood Vessels in lung affected with *Aspergillus fumigatus*. Fig (10): congested blood vessels and thrombus formation, in addition to granuloma with microgranulomas formation that found focally in lung tissues affected with *E.coli* O125 and *Aspergillus fumigatus*. Fig (11): marked dilatation of 2ry bronchial with hyperplasia of the lining epithelium, submucosal hemorrhage and edema in addition to fibrin purulent exudate in lung affected with *E.coli* O125 and *Aspergillus fumigatus*.

infection. In this study, postmortem examination of *E. coli* infected chicks either naturally or experimentally revealed congested lungs (pneumonia), mucopurulent nasal discharges, airsacculities and yellow cheesy materials on lungs and airsacs, pericardities and perihepatites. This result agrees with Islam et al. (2004), Ask et al. (2006) and Dhelly (2011) they reported that, the postmortem lesions of *E. coli* infection included airsacculities, pneumonia, pericardities and perihepatites. In our study the decrease in body weight by about 20% than normal in chicks that experimentally infected by *E. coli* O125 agree with Ewers et al. (2003) who reported that, avian pathogenic *E. coli* (APEC) cause disturbance of the digestion and nutrient absorption and cause decrease body weight, elevate feed conversions and reduced livability. In this study, mortality

rate in chicks that experimentally infected with *E. coli* O125 was 26.6% along 21 days post infection. This result closely similar to Raji et al (2003) and Fan et al. (2004) who showed mortality 20-40% and 28.1% respectively. But this result disagrees with Rosenberger et al. (1985) who reported mortality in *E. coli* infected one day old broiler chicks increased to 60% when inoculated intratracheally by *E. coli* strains isolated from broiler chickens. The difference may be attributed to difference in the strains or route of infection. On the other hand our result was higher than Islam et al. (2004) who reported mortality in *E. coli* inoculated chicks was 6.5% but did not mention the strain of *E. coli* so this difference also may be attributed to difference in the inoculated strains. In the present study histopathological examination of lung tissues of broiler chicks



that experimentally infected by *E. coli* O125 showed that, at the first week congestion of pulmonary blood vessels with thickening of its wall, followed by severe hyperemic pulmonary blood vessels with thrombus formation, edema in epith lining blood vessels and formation of microgranuloma in parabroncheal lumen were all seen. In advanced stage, thrombus formation occur in blood vessels and formation of microgranuloma and granuloma in lung tissues, Hyperplasia of lining epith of bronchiole, clusters of bacteria observed in granuloma, sloughed epith and dead heterophily and fibrinopurulent exudates were observed. This result agree with Esther-Maria Antao et al. (2008).

In present study the prevalence of *Aspergillus* spp in collected broiler chicks was 43%. This result agree with Reis et al. (1955) and Chute et al. (1956) who considered *Aspergillosis* as the most important respiratory fungal infection in birds. On the other hand in this study *Aspergillus fumigatus* was present at percentage 75% from total isolated *Aspergillus* spp. This result agree with Raper et al., (1965) and Ainsowrth (1949) who reported that, *Aspergillus fumigatus* is the most isolated cause of *Aspergillosis* in poultry. On aspect of clinical signs, the present study revealed that, the broiler chicks that infected by *Aspergillus* SPP either naturally or experimentally were showed gasping. This result agree with Francoise Femenia et al., (2007), Musa et al., (2014) and Jacquie Jacob (2015) they observed gasping in birds infected with *aspergillosis*.

In this study the postmortem examination of chicks that have *Aspergillus* spp showed congested lungs, white or yellowish cheesy material on lungs and/or airsacs and white nodules on lungs. This result agree with Edrees (1986) and El-Badry (1979) who recorded the presence of congested lungs and airsacculities and yellowish caseous material on lungs of chicks that have *aspergillosis*, Also this result agree with Goreon (1956), El-Batrawy (1980), Abdel

Hamid and Hassieb (1987) and Sajid et al (2006) who reported that, the presence of white to yellowish nodules on lungs as a characteristic lesion of *aspergillosis*. In this study, mortality rate in experimentally infected one day old broiler chicks with *Aspergillus fumigatus* was (3 chicks from 30 chicks) at percentage of 10% at first week. This result agree with result of Chark et al., (1954) and Remdan (1989) who recorded the mortality rate of *aspergillosis* (1-10%) and 8% respectively. While Richard et al., (1981) and Dayar et al., (1984) reported the mortality rate in Turkey poults infected by *Aspergillus fumigatus* was 50% and 33% respectively. At present study, histopathological examination of lung tissues of broiler chicks that experimentally infected by *aspergillus fumigatus* revealed congestion of pulmonary blood vessels with thickening its wall at the first and second day postinfection then no mortality until 11th day where *Aspergillus* was not isolated. This result agree with result of Francoise femenia et al., (2007) who reported that, the histopathological lesions of *aspergillosis* appear on lung tissues after 2-3 days of infection then this lesions were reduced at 7th day postinfection, but this result disagree with Kunkle et al., (1998) who found lymphocytes and macrophages. This may be attributed to that, these authors did not mentioned the time after infection that needed to produce this lesions was reported at their studies.

To the best of our knowledge there are no available data about dual infection of both *E.coli* and *Aspergillus* infection in broilers.

In present study, it is clear that the dual infection with *E. coli* O125 and *Aspergillus fumigatus* had more bad effect on broiler chickens with respect to the clinical signs, P.M lesions, mortality rate and growth performance compared with single infection with *E.coli* O125 or *Aspergillus fumigatus*.

## 5. REFERENCES

- Abd El-Galil, El Bakry, M., Ammar, A. 1983. Bacterial causes of early chicks mortalities in Sharkia governorate "vet. Med. J. 31 (3): 255-265.
- Abd El-Hamid, H.S., Hassieb, M.M. 1987. "Pathogenicity of *aspergillus flavus* and *aspergillus niger* isolated from poultry feedstuffs Proc. Ist Annual conf. of the Egypt. Vet. Poult. Assoc., pp. 65.
- Abusalab, M.M., Gumaa, S.A., Mulla, Omer, M.M. 2010. "Outbreak of colibacillosis among Broiler and layer Flocks in Intensive and semi intensive poultry farms in Kassala state, Eastern Sudan" *Asian Journal of poultry science*, 4: 173-181.
- Ainsoworth, G.C., Rewoll, R.E. 1949. "The incidence of aspergillosis in captive wild birds" *J. comp. Path.* 59, 213.
- Al-Badry, A. 1979. "A study on mycotic diseases in turkeys". Thesis to Faculty of Vet. Med. Assuit. Univ. Egypt.
- Arora, A.K., Gupta, S.C., Kaushik, R.K. 1987. "Detection of upper respiratory tract bacterial carriers in poultry". *Ind. Vet. Med. J.* 10(2): 63-67.
- ASK, B., Van der Waaij, E.H., Van Arendonk, J.A., Stegerman, J.A., 2006. "Defining susceptibility of broiler chicks to colibacillosis". *Avian Pathol*, 35(2): 147-153.
- Barners, H.J., Nolan, L.K., Vaillancourt, J.P. 2008. "Colibacillosis. PP. 691-732. *Indiseseases of poultry*, 12th ed, Saif YM, Fadly AM, Glisson JR, McDougold L.R, Nolan LK, Swayone DE (Ed), Blackwell Pub. Professional, Ames, Iowa.
- Blanco, J.E., Blanco, M., Mora, A., Jansen, W.H., Garcia, V., Vazquez, M.L., Blanco, J. 1998. Serotypes of *Escherichia coli* isolated from septicaemic chickens in Galicia (northern Spain). "Vet. Microbial. 61(3): 229-235.
- Boumel, C.P., Imerman, J., Trampel, D. 2000. "Jowa's Turkey industry an economic review In S. Thompson (ed). Jowa state Univ. Agriculture and home economics experiment station.
- Chen, Jiajua, Y., Haixia, H., Song, G., Xinan, J., Xiufan, L. 2012. "Serogroups, pathogenicity and virulence – associated genes of avian *E. coli* isolates collected in China". *African Journal of Microbiology Research*. 6 (5), pp: 1001-1007.
- Chute, H.L., O'Meara, D.C., Tresner, H.D., La combe, E. 1956. The fungus flora of chickens with infection of respiratory tract. *Am J vet Res* 17: 763-765.
- Chark, D.S., Jones, E.E., Crowl, W.B., Ross, F.K. 1954. Aspergillosis in newly hatched chicks. *J. Am. Vet Med. Assoc.* 124: 116-117.
- Dheilly, A., Boudier, A., Le Devender, L., Kempf, I. 2011. Clinical and microbial efficacy of antimicrobial treatment of experimental avian colibacillosis". *Veterinary Microbiology* 149 (3-4): 422-429.
- Dwars, R.M., Matthijs, M.G.R., Daemen, A.J.J.M., Van-Eck, J.H.H., Landman, W.J.M. 2009. "Progression of lesions in the respiratory tract of broilers after single infection with *Escherichia coli* compared to superinfection with *E. coli* after infection by infectious bronchitis virus. *Vet immunology and immunopathology*. 127(1-2): 65-76.
- Dyar, P.M. 1984. Aspergillosis in Turkeys associated with use of contaminated litter. *Avian Dis.* 28: 250-255.
- Edrees. 1986. "Studies on pathogenic fungi in poultry and the effect of Antifungal drugs". Ph.D. Thesis to vet. Med. Fac, Assuit Univ. Egypt.
- El-Batrawy, A.M. 1980. "Studies on mycotic infections in poultry with particular reference to *A. fumigatus* infection in intensive poultry farms". Ph.D Thesis to Fac. Vet. Med. Cairo. Univ.
- Esther-Maria AntosLothar, H., Wieler, Christa Ewers 2008. "Adhesive threads of extraintestinal pathogenic

- Escherichia coli” “Gut pathogens (2009), 1:22 doi: 10.1186/1757 – 4749-1-22.
- Ewers, C., Janssen, T., Wieler, L.H. 2003. “Avian pathogenic E. coli (APEC)”. Berl-munch. Tierarztl. Wochenscher. 116 (9-10): 381-395.
- Ewers, C., Wieler, L.H. 2004. “Molecule characteristics of Escherichia coli serogroup O78 strains isolated from diarrheal cases in bovines urge further investigations on their zoonotic potential. Mol. Nutr. Food. Res. 2004 Dec; 48 (7): 504-14.
- Fan, Hoovr, G.J., Unter, D.B., Hayes. 2004. “Virulence Factors of Avian pathogenic E. coli isolated from broilers from the south of Brazil”. Avian. Dis. 46(3): 749-753.
- Françoise Femina, Jean Jacques Fontaine, Jacques Guillot 2007. “Clinical mycological and pathological findings in turkeys experimentally infected by *Aspergillus fumigatus*”. Avian pathology 36(3), 213-219.
- Ghosh, S.S. 1987. “E. coli serotypes of poultry in Nagaland”. Indian J. of Ani. Res. (22) 35-38. Ind. Vet. J. 64(6): 464 -466.
- Goreon, R.F. 1956. “Differential diagnosis and control of respiratory diseases in poultry”. Vet. Rec. 68, 547.
- Gross, W.B. 1994. “Diseases due to E. coli in poultry”. In C.L. Gyles (ed). E.coli in Domestic Animal and Humans”. CAB Int’l: Wallingford, UK, 237-260.
- Ibrahim, A.I., El-Atter, A.A., El Shabidy, M.S. 1998. “Studies on E. coli isolates from respiratory affected broilers and protection evaluation of different prepared bacterins”. Assuit. Vet. Med. J. 37(74): 152-156.
- Islam, M.A., Samad, M.A., Kabir, S.M.L. 2004. “Characterization and antibiogram of E. coli associated with mortality in broilers and Duckling in Bangladesh”. Bangl. J. Vet. Med.2 (1): 9-14
- Jacque Jacob 2015. “Aspergillosis in poultry University of Kentucky.
- Javed, M.T., Anjum, R., Khan, A. 1991. “Studies on the isolation, pathogenicity and sensitivity of E.coli in layers and broilers”. Parcistan – vet. J, 11: 187-190.
- Khalid, A.M. 1990. “Studies on natural and experimental E. coli infection in chickens”. J. Egypt. Vet. Med. Ass., 50 (3): 379-389.
- Kunkle, R.A., Rimler, R.B. 1998. “Early pulmonary lesions in turkeys produced by nonviable *aspergillus fumigatus* and/or *pasturellamulticoda*”. Avian Dis. 42: 770-780.
- Martin, A., Palomino, U.C. 2009. “Procedures manual, Nitrate Reductase Assay (NRA): Drug susceptibility testing for mycobacterium tuberculosis, Institute of tropical medicine, mycobacteriology Unit, Antwerp, Belgium: 1-12.
- Musa, I.W., Ismail, A. 2014. “Aspergillosis in Broilers: reports of three cases from a commercial and tow broiler breeder farms in Zaria, Nigeria”. Int. J. Curr. Microbial. App. Sci.
- Pier, A.C., Richard, J.L. 1992. “Mycosis and mycotoxicosis of animals caused by *Aspergillus* in *Aspergillus*: Biology and Industrial Application. Butterworth. Heinemann: Stoneham, MA.
- Piercy, D.W.T., West, B. 1976. “Experimental E.coli infection in broiler chickens”. Course of the disease induced by inoculation via the air sacroute”. J. comp. pathol, 86: 203-210.
- Raji, J.O., Adekeye, J.K.P., Kwaga, Bale, J.O.O. 2003. “In vitro and in vivo pathogenicity studies of E. coli isolated from poultry in Nigeria”. 58(1) 2003.
- Raper, K.B., Fennel, D.I. 1965. “The genus *Aspergillus*. The Williams and Wilkins Co.: Baltimore, MD, 686.

- Redman, V.T., Schildger, B. 1989. "Therapeutischer Einsatz von Enilconazol bei Broiler - Küken mit Aspergillose. Deutsche tierärztliche Wochenschrift 96: 15-17.
- Richard, J.L., Culp, R.C., Thustron, J.R., Songer, J. 1981. "Response of turkey poults to aerosolized spores of *Aspergillus fumigatus* and of latrogenic and non-toxigenic strains of *A. flavus*". Avian Dis. 25: 53-67.
- Reis, J. 1955. "Queratomycose aspergilicaepizootica em pintos. Arquivos do Instituto Biológico: saopaulo, Brazil 11: 437-462.
- Rosenberger, J.K., Fries, P.A., Cloud, S.S., Wilson, R.A. 1985. "In vitro and in vivo characterization of avian *E. coli*, and factors associated with pathogenicity. Avian Dis. 29: 1094-1107.
- Sajid, I.A., Khan, U.R. 2006. "Aspergillus fumigatus in commercial poultry flocks, A serious threat to poultry industry in Pakistan". J. Anim. Pl. Sci. 16 (3-4): 2006.
- Verma, K.C., Aldakha, S.C. 1971. "E. coli other enterobacteriaceae group of organisms from different pathological condition in poultry. Ind. Vet. J. 48: 107-108.