



## Some Morphological Studies on the Quadratomandibular joint of Ostrich (*Struthio camelus*)

Safwat Ali

Department of Anatomy and Embryology, Faculty of Veterinary medicine, Minia University, Egypt. [asafawato@yahoo.com](mailto:asafawato@yahoo.com)

### ABSTRACT

The current study aimed to give detailed information about the morphology of the quadratomandibular joint in ostrich. This study was done on fifteen ostrich heads of both sex. The gross morphological features of the articular surfaces and capsule associated with the joint were thoroughly investigated. At the quadratomandibular joint the quadrate bone is interposed between the mandible, jugal and pterygoid on the one hand and the squamous and basisphenoid bones on the other hand with a congruent articular surfaces. The joint capsule contains elastic fibers, with two main condensations, the rostral one, the quadrojugalmandibular ligament, and a very strong caudal one, occipitomandibular ligament. suitable sites for the intra-articular injection of this joint in ostrich was determined, which might be useful in treatment joints affections. Computed tomographic imaging of the quadratomandibular joint was used for evaluation due to its contrast resolution and its ability to have imaging for demonstration of the functionality of the joint. Relevant normal anatomy and results of were discussed for better understanding of the joint morphology.

**Keywords:** Quadrato mandibular joint, Ostrich, Computed tomography, quadrate bone

(<http://www.bvmj.bu.edu.eg>)

(BVMJ-29(2): 319-325, 2015)

### 1. INTRODUCTION

Ostrich (camel bird) (*Struthio camelus*) is the largest living bird, usually survives in bands of 10-50 individuals, unable to fly (ratites), spends its time walking, only running if threatened (60-70 km/h) (Deeming, 1996). The ostrich, or the 'camel bird' because of its similarities with dromedaries, based on the Greek and Latin name "*Strutho camelus*" (Bertram, 1992). Over the past 10-15 years, ostrich meat has become an increasingly important product and ostrich farming has increased in popularity (Smith et al., 1995; Drenowatz et al, 1995). Recently, the importance of the ostrich as a new source of animal protein and its byproducts productions attracts many authors such as (Jamroz, 2000) to study the morphology of this bird. The anatomy of the ostrich has been studied for many years. The comparisons between the

bony palates of different birds led to their division into palaeognathic (primitive) and neognathic (modern) birds. The ostrich is a ratite, palaeognathic bird. Few data are recorded on the anatomy of the quadratomandibular joint on this bird and so this study is a trial to give the possible anatomical information about the normal structures of the quadratomandibular joint using new techniques such as computed tomography (CT). Detailed descriptions of the osteology of the ostrich skull are provided by Bock (1963). The skull of the ostrich is typically avian and although it is palaeognathic, there are many cranial features that are neotenic in relation to other palaeognathic and neognathic birds. The increasing importance of birds as an important source of meat and egg production lead to increase the interest in

studying avian structures and function (Louw and Seely, 1984). The gross anatomy of the quadratomandibular joint in different species of birds was studied by (Dyce et al., 2002; King and McLelland, 1984; Nickel et al., 1977), however detailed information about the morphology and CT of the quadratomandibular joint of ostrich still deficient. The present work was performed to obtain some details on the morphological features using the gross morphological studies in addition to CT of the quadratomandibular joint in ostrich. The suitable site of the intra-articular injection of the studied joint was determined.

## 2. MATERIALS AND METHODS

The present work was carried out on fifteen heads of adult ostriches of both sex. Freshly slaughtered healthy adult ostriches obtained from the slaughter house of Lion village, Beheira Governorate, Egypt. Eight specimens were freshly dissected to explain the morphological structure. Two specimens were prepared for studying the articular surfaces entering in the formation of the joint. Two specimens were used to study the site of the intra-articular injection. Computed tomographic (CT) studies were done on the remaining three specimens.

Dissected samples were photographed and images were processed on the computer. The heads were underwent consecutive CT scan using CT scanner [TOSHIBA 600HQ, third-generation equip TCT, Japan] at Minia University Hospital, El-Minia, Egypt. The acquisition settings were 120 kv, 100 mAs and 0.8 mm slices of thickness and imaged with a closed bill. The images were started at the tip of the bill and continuing caudally to the level of first cervical vertebrae. The official nomenclature used in this study was adopted according to (Nomina Anatomica Avium, 1993)

## 3. RESULTS

At the quadratomandibular joint the quadrate bone is interposed between the mandible, jugal and pterygoid bones and the squamous and basisphenoid bones (Fig. 1). The quadratomandibular joint was positioned at the same level of the dorsal border of the ramus of the mandible.

### 3.1. *The articular surfaces of the quadratomandibular joint:*

The joint is formed by the quadrate bone and the articular bone of the mandible. The articular surfaces of the joint included the articular surface of the mandible and the mandibular process of the quadrate bone.

#### 3.1.1. *Os quadratum:*

The quadrate bone consists of body; corpus ossis quadrati and three processes; mandibular, otic and orbital. Proc. The mandibular process, mandibularis quadrati of the quadrate bone is the most developed one and carried ventrally two condyles to achieve the articulation with the mandible. The two condyles; medial and lateral ones (Condylus medialis and Condylus lateralis respectively). The medial condyle was larger and very prominent than the lateral one extending more ventrally to articulate with the medial cotyla of the mandible. Condylus pterygoideus *Os quadratum*, is an articular surface on the medial aspect of the mandibular process for articulation with the lateral end of *Os pterygoideum*. The lateral; smaller condyle of the mandibular process of quadrate bone made articulation with the lateral cotyla of the mandible. Moreover, the lateral condyle carried cotyla quadratojugalis located on the root of the lateral condyle of the mandibular process of *Os quadratum* for articulation with the quadratojugal bone. The two condyles separated by a wide groove; Sulcus intercondylaris. Proc. oticus quadrati, the otic process of the quadrate bone articulates with a cup shaped articular facet on the temporal bone. The tympanic surface of the otic process (Facies tympanica) and upper body of the quadrate bone forms with Ala

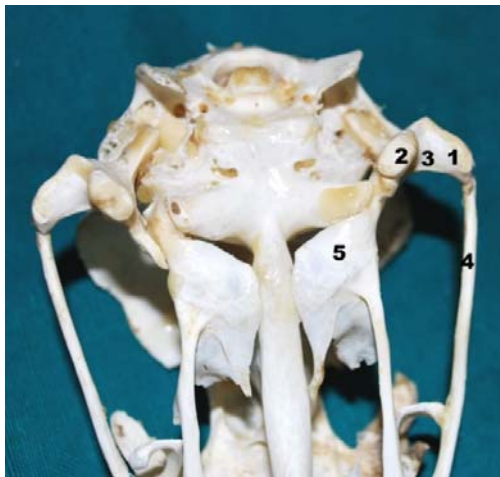
parasphenoidea the rostral wall of the tympanic cavity. Proc. orbitalis quadrati, the orbital process of the quadrate bone is wide with free end extends medially toward the orbit (Fig. 1& 3).

### 3.1.2. Ossamandibulae:

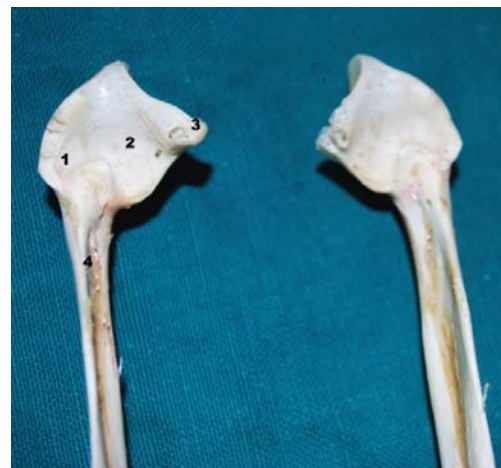The mandibular articular surfaces of quadratomandibular joint composed of a Fossa articularis quadratic; an area of the mandible for articulation with the condyles of quadrate bone. There were two cavities; Cotylae fossae articularis. These are the facets for articulation with the condyles of the Os quadratum. The medial cotyla; Cotyla medialis, was relatively large and separated from the lateral one by Tuberculum intercotylare. The medial cotyla carried medially a medial mandibular process (Proc. medialis mandibulae) prominent and projected medially with its

tip curved dorsally (Fig. 2). It carry dorsally a Foramen pneumaticum articulare, an opening in the upper surface of Proc. medialis mandibulae with a diameter of 1.2-1.6 mm that leads to pneumatic spaces in the caudal segment of the mandibular ramus (Ramus mandibulae). The Cotyla lateralis was smaller and articulates with the lateral condyle of the quadrate bone.

These cotylae with surfaces of the quadrate bone gives the joint a congruent appearance. The retroarticular process; Proc. retroarticularis is a dorsoventral elongation, joined the medial mandibular process dorsally and ventrally with a ridge like forming a triangular fossa (Fossa caudalis) which is a shallow concavity of the caudal surface of Proc. mandibulae medialis, located medial to the retroarticular process, this is the area for insertion of M. depressor mandibulae.



**Fig. 1:** Photograph of the skull of the adult ostrich (ventral view) showing 1- Condylus lateralis, 2- Condylus medialis, 3- Sulcus intercondylaris, 4- Os jugale 5- Os pterygoideum



**Figure 2.** Photograph of the mandible of the ostrich (dorsal view) showing 1-Cotyla lateralis 2-Cotyla medialis, 3- Proc. medialis mandibulae, 4-Ramus mandibulae

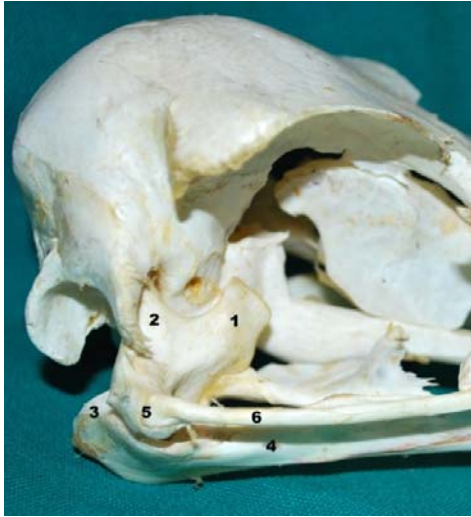### 3.1.3. Articular capsule (Capsule articularis)

The fibrous capsule (Capsula fibrosa) was thick and tightly attached to the margin of the articular surfaces. It extended dorsally to end at the postorbital process of the temporal bone. Ventrally, the fibrous capsule is attached about 0.3 cm from the articular margin of the articular bone of the

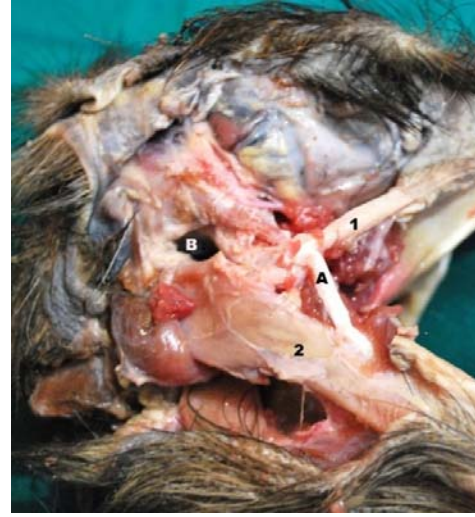mandible. rostrally covering the lateral aspect of the caudal part of the quadratojugal bone and extended caudally till the zygomatic process of the temporal bone. The fibrous capsule contains numerous elastic fibers. Some of it condenses to form ligaments, the rostral condensation, forming quadratojugo-mandibular ligament (Lig. quadratojugo-

mandibularae), which is detached from the side of the quadratojugal bone and receive some fibers from the mandibular process of quadrate bone and extends rostroventrally to end about 2.5 cm rostral to mandibular articular surface. It stretches during opening of the beak. The caudal condensation of the fibrous joint capsule, Occipitomandibular ligament (Lig. occipitomandibulare) is a strong ligament, extends between tympanic

wing (Ala tympani) of Os exoccipitale and the caudomedial aspect of the mandibular process. The ligament forms the caudal wall of the tympanic cavity. Caudal edge of the ligament serves as home to the deep portion of the M. depressor mandibulae. The synovial layer of the capsule was thin and limited only to the articular margin of the joint (Fig.5&6).



**Fig. 3:** Photograph of the skull of the ostrich (lateral view), right side quadratomandibular joint showing: 1-Proc. orbitalis quadrati, 2- Proc. oticus quadrati, 3- Proc. Retroarticularis, 4- Ramus mandibulae, 5- Os quadratojugale 6- Os jugale,



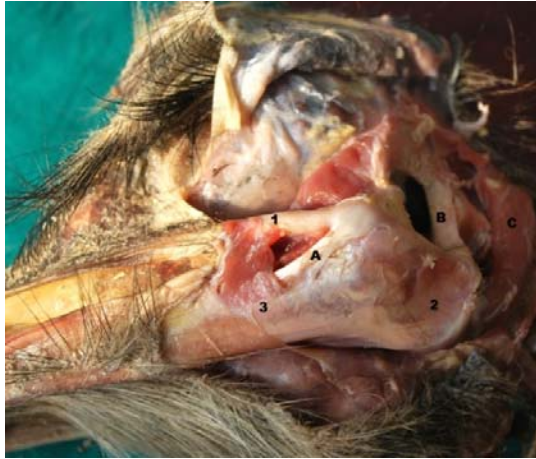**Fig. 4:** Photograph of the head of the ostrich (lateral view), right side quadratomandibular joint showing: 1- Os jugale, 2- Ramus mandibulae, A- Lig. Quadratojugo-mandibularae B- Meatus acusticus externus

### 3.2. Site of intra-articular injection:

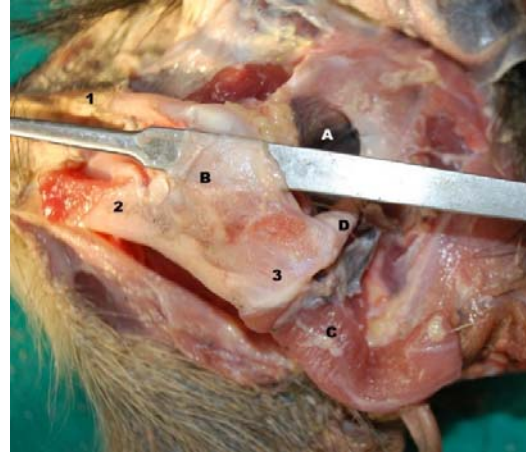Caudal approach, the suitable site of injection inside the joint cavity was just above the retroarticular process which could be palpated from outside, and ventral to the external acoustic meatus, needle should be introduced rostroventrally for about 1 cm to be inside the joint cavity. Rostral approach, injection site of the joint could be achieved by introduction of the needle about 2 cm caudal to the angle of the mouth at the level of the lateral canthus of the eye in a caudomedial direction and slightly ventral. The first site is preferable and easy approached (Fig. 7).

### 3.3. Computed tomography:

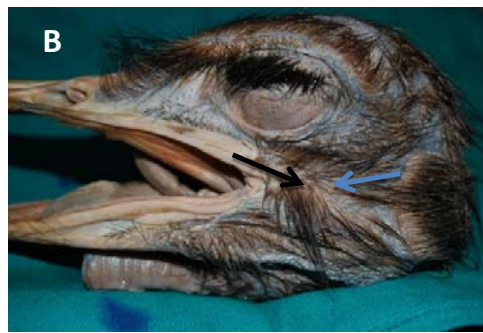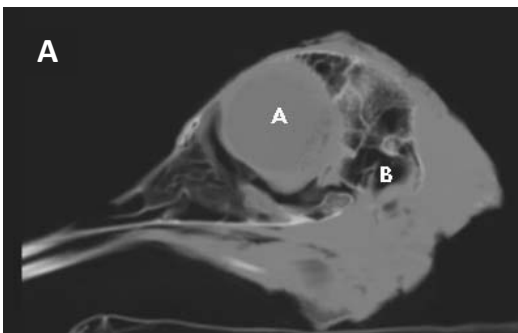
Identifiable anatomical structures were labeled with their analogous corresponding CT images. The bones of the quadratomandibular joint were the densest tissue in the CT. The articular surface of ostrich appeared as the whitest hyper dense with black areas inside the bones due to presence of air inside (Pneumatic bones), soft tissue around the joint were seen with various gray scales on the CT images (Fig. 8). The CT images provided a good view of the bony structures quadratomandibular joint of the in its natural position and corresponding to the anatomical description. Intra-articular injection sites were determined on CT images in correspondence with that of gross anatomical results (Fig. 7).



**Fig. 5:** Photograph of the head of the ostrich (lateral view), left side of quadratomandibular joint showing: 1- Os jugale, 2- Proc. Retroarticularis, 3- Ramus mandibulae, A- Lig. Quadratojugomandibularae, B- Lig. Occipitomandibulare, C- M. depressor mandibulae



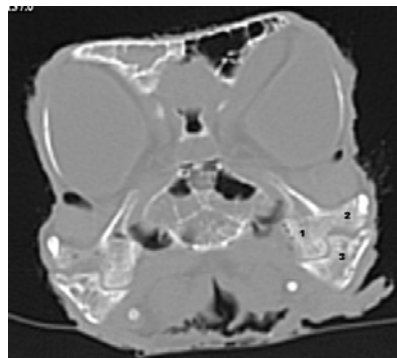
**Fig.6:** Photograph of the head of the ostrich (lateral view), left side. 1- Os jugale, 2- Ramus mandibulae, 3- Proc. Retroarticularis A- Meatus acusticus externus, B- Capsula fibrosa, C- M. depressor mandibulae, D- Lig. Occipitomandibulare



**Figure 7. A:** CT image of adult ostrich head A-the Orbit, B- Meatus acoustic externus compared with **B:** The photograph of the head of the ostrich (lateral view), left side: showing the suitable sites of intra-articular injection, blue arrow, caudal approach while black arrow pointed to the rostral approach

**Fig. 8:** CT image of adult ostrich head showing the quadratomandibular joint. 1- Condylus medialis, 2- Condylus lateralis, 3- Cotyla medialis and Cotyla lateralis separated by Tuberculum intercotylare.

**Note:** the similarity with Fig.1, Congruence of the articular surfaces is clear and absence of inter-articular disc



#### 4. DISCUSSION

The quadrate bone is a keystone of cranial movement, as it articulates with the squamosal, pterygoid, jugal and mandible with agreement of previous studies in domestic birds (Dawson et al., 2011; McLelland, 1990, Dyce et al., 2002). Previous studies of quadrate movement during feeding in birds have suggested that the quadrate rotates primarily about one axis, swinging in a rostral or rostromedial direction toward the pterygoid, thereby elevating the upper bill (Gusseklou et al., 2001). However, the quadrate bone of ostrich has a well-defined, bicondylar articulation with the squamosal (Cracraft, 1986; Elzanowski et al., 2000), Moreover, the results revealed that the mandibular process of the quadrate bone of ostrich (palaeognathic bird) has two condyles articulate with two cotylae of the mandible agreed with (Imam and El-Mahdy, 2004), however, in the neognathic, the mandibular process of the quadrate bone possess three articular process (Baumel, 1979; Hassan, 2012). They are articular surfaces of the quadratomandibular joint of ostrich were congruent, and no intra-articular disc observed, this finding unlike that of temporomandibular joint in domestic animals where the presence of intra-articular disc is essential (Erasha, 2000; Dyce et al. 2002). The results obtained in this study similar to that reported by (Imam and El-Mahdy, 2004) in that the fibrous capsule contains many elastic fibers, two condensations, the rostral one, quadrojugalmandibular ligament, and a very strong caudal one, occipitomandibular ligament, but differ with the same authors in that the quadromandibular ligament was absent in this study. It is suggesting that these ligaments between the skull and mandible in addition to interlocking jaw joint play an important role in the kinematics of the bill (Dawson et al., 2011; Zusi, 1967). Moreover, they may control the opening of the bill. The given results described an easy approach for intra-

articular injection of the quadratomandibular joint which differ from that obtained by (Imam and El-Mahdy, 2004). Regarding the CT scan of the quadratomandibular joint, the results revealed that CT images give a good view of the bony structure of the joint however, not give a clear identification about the soft tissue around it.

#### 5. REFERENCES

- Baumel, J.J. 1979. Systema cardiovasculare. In *Nomina Anatomica Avium*. ed. by Baumel, J.J.; King, A.S.; Lucas, A.M.; Breazile, J.E. and Evans, H.E., London, New York, Academic Press.
- Bertram, B.C.R. 1992. *The Ostrich Communal Nesting System*. Princeton University Press, Princeton, New Jersey.
- Bock, W.J. 1963. The cranial evidence for ratite affinities. *Proceedings of the XIII International Ornithological Congress* 13: 39-54
- Bock, W. J. 1964. Kinetics of the avian skull. *J. Morphol.* 114: 1-42.
- Cracraft, J. 1986. The origin and early diversification of birds. *Paleobiology* 12: 383-399.
- Dawson, M.M., Metzger, K.A., Baier, D.B., Brainerd, E.L. 2011. Kinematics of the quadrate bone during feeding in mallard ducks. *Journal of Experimental Biology*. 214: 2036-2046.
- Deeming, D.C. and Angel, C.R. 1996. Introduction to the ratites and farming operations around the world. In: Deeming, D.C. (ed.) *Improving our Understanding of Ratites in a Farming Environment*. Ratite Conference, Oxfordshire, UK, pp. 1-4.
- Drenowatz, C, Sales, J.D., Sarasqueta, D.V and Weilbrenner, A. 1995. History and geography. In: Drenowatz, C. (ed.) *The Ratite Encyclopedia*. Ratite

- Records, San Antonio, Texas, pp. 3-29.
- Dyce, K.M.; Sack, W.O. and Wensing, C.J.G. 2002. Textbook of Veterinary Anatomy. 3rd ed. Saunders, Philadelphia, London, New York, St. Louis, Sydney, Toronto. pp. 802, 803.
- Elzanowski, A., Paul, G. S. and Stidham, T. A. 2000. An avian quadrate from the Late Cretaceous Lance Formation of Wyoming. *J. Vertebr. Paleontol.* 20: 712-719.
- Erasha, AM. 2000. "Anatomical and radiographic observation on the tempromandibular joint articulation in various mammals, part 1: Ruminant" *Vet. Med. J. Giza*, 40:(3): 9-16
- Gussekloo, S. W. S. and Bout, R. G. (2005). Cranial kinesis in palaeognathous birds. *J. Exp. Biol.* 208: 3409-3419.
- Hassan, S. A. 2012. Comparative Morphological Studies on the Quadrate-mandibular Articulation in Hooded Crow (*Corvus cornix*) and Cattle Egret (*Bubulcus ibis*). *J. Vet. Anat.*, 5: 31-46.
- Imam, H. M. and Elmahdy, O. M. 2004. Some anatomical studies on the quadrate-mandibular articulation of ostrich (*Struthio camelus*) and Flamingo (*Phoenicopterus ruber*). *Assiut Vet. Med. J.* 50: 1-20
- Jamroz, D. 2000. Feeding ostriches and emus — physiological basis and nutritional requirements — a review. *Prace Materialy Zootechniczne* 56: 51-73.
- King, A.S. and McLelland, J. 1984. *Birds, their Structure and Function*. Bailliere Tindall, London.
- Louw, G.N. and Seely, M.K. 1984. "Ecology of desert organisms." Pp. 64-65, Longman, London and New York.
- McLelland, J., 1990. "A color atlas of avian anatomy" Wolfe Publishing Ltd.
- Nickel, R.; Schummer, A. and Seiferle, E. 1977: *Anatomy of the Domestic Birds*, chapter (blood and vascular system), Verlag Paul Parey.
- Nomina Anatomica Avium 1993. International Committee on Avian Anatomical Nomenclature, a committee of the World Association of Veterinary Anatomists, 2nd Edition, Cambridge, Massachusetts.
- Smith, W.A., Cilliers, S.C., Mellett, ED. and van Schalkwyk, S.J. 1995. Ostrich production - a South African perspective. In: Lyons, TP and Jacques, K.A. (eds), *Biotechnology in the Feed Industry*. Proceedings of the 11th Alltech Annual Symposium. Nottingham University Press, Nottingham, pp. 175-198.
- Swart, D. 1988. Studies on the hatching, growth and energy metabolism of ostrich chicks *Struthio camelus* var. *domesticus*. PhD thesis, University of Stellenbosch.
- Zusi, R. L. 1967. The role of the depressor mandibulae muscle in kinesis of the avian skull. *Proc. U. S. Nat. Mus. Smith. Inst.* 123: 1-23.